

Orthopedics

KEYWORDS: Adhesive capsulitis, glenohumeral joint, hydraulic distension procedure, HYDRODILATATION

EFFECTIVENESS OF THE HYDRODILATATION ON ADHESIVE CAPSULITIS OF SHOULDER: A TEN-YEAR META ANALYSIS



Volume-3, Issue-2, February - 2018

Alyne Mendonça Marques Ton*

*Corresponding Author lyne_msv@hotmail.com

Article History
 Received: 27.10.2017
 Accepted: 14.12.2017
 Published: 10.02.2018



ABSTRACT:

Adhesive capsulitis, or frozen shoulder syndrome, is a common condition that results in pain and overall restriction of movement in the glenohumeral joint. Several treatments have been described for adhesive capsulitis of the shoulder, including hydraulic distension. This meta-analysis study aims to evaluate the efficacy of hydraulic distension in the treatment of patients with adhesive capsulitis of the shoulder in the last 20 years. Therefore, because of the limited number of validated clinical trials and the varying outcomes of follow-up, it was impossible to analyse the influence of other clinically relevant factors, such as the severity of local pain prior to the procedure, the use of additional medications, and the volume of fluid used in the hydraulic distension procedure, as well as to define the existence of superiority of the procedure in relation to the other existing treatment methods.

INTRODUCTION

Adhesive capsulitis, or frozen shoulder syndrome, is a common condition that results in pain and overall restriction of movement in the glenohumeral joint.^{1,2,3,4,14,15} The prevalence of this condition is approximately 2-5% in the general population, reaching rates exceeding 10% in the diabetic population.^{5,6,7,8} It is a self-limiting condition lasting approximately 18 to 30 months.^{9,10,15} However, follow-up studies have demonstrated residual pain and joint stiffness in the affected shoulder in about 50% of patients, with functional limitation in 11% after a follow-up period of 7 years.⁸

The exact cause remains unknown, although it is more common in women over the age of 40 in individuals with the Human Leukocyte Antigen B27.¹¹ The diagnosis is primarily clinical with characteristic findings of night pain and significant functional impairment predominantly to external rotation.^{3,8,10,14,15}

According to Ferreira-Filho (2005) in their review on the subject, the progressive alterations presented can be characterised in four characteristic stages. In stage I, called the pre-adhesive stage, there is an inflammatory synovial reaction; in stage II, called adhesive synovitis, there is proliferative synovitis and the beginning of the collapse of the articular recess walls and adhesions of the joint capsule on the humeral head; in stage III, maturation, regression of the synovitis and collapse of the axillary recess occurs; and in stage IV, called chronic, the adhesions are mature, strongly restricting the movements of the humeral head in relation to the glenoid.¹⁵

Several treatments have been described for adhesive capsulitis of the shoulder, including hydraulic distension (HD). Hydraulic distension involves distension of the glenohumeral joint through local injection of fluids, leading to pain reduction and recovery of motor ability by stretching and/or rupture of the joint capsule. This procedure was first described by Andren and Lundberg in 1965.¹²

Since then, a large number of researchers have studied the effects of treatment with hydraulic distension and several benefits have been reported. However, most studies have limitations with regard to the quality of evidence.

METHODOLOGY

This meta-analysis study aims to evaluate the efficacy of hydraulic distension in the treatment of patients with adhesive capsulitis of the shoulder.

A systematic review of the literature was conducted, with meta-analysis, of the clinical trials published in the Pubmed, Cochrane Library and Medline databases in the last 10 years, using the keywords 'stiff shoulder', 'frozen shoulder', 'adhesive capsulitis', 'hydrodilatation' and 'hydraulic distension'.

RESULTS

The literature research using the described terms showed 363 relevant articles: 156 in Pubmed, 194 in the Cochrane Library and 13 in Medline, of which 72 were excluded as they were duplicates. All the remaining articles were submitted to a careful manual analysis by 2 authors through the reading of the abstract, and the prospective studies, the research target of which involved patients with primary adhesive capsulitis submitted to hydraulic distension, having been analysed.

Retrospective studies, follow-up studies, editorials, literature reviews, and studies the research target of which was not mentioned above and/or the methodology of which was unclear with respect to the design employed were excluded. Finally, 269 patients were included in 4 randomised, uncontrolled clinical trials.^{1,2,3,4} (Figure 1).

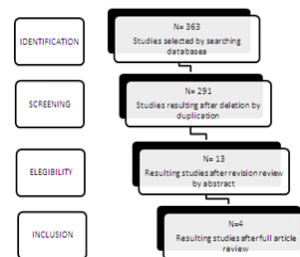


Figure 1: Diagram indicating the selection of the studies for inclusion in the meta-analysis

Two reviewers independently assessed the methodological quality of the trials included, using a 12-item scale.¹³ The weighted kappa of agreement in the analysis of the quality of the clinical trial among the reviewers was 0.88 (95% with a confidence interval of 0.78-0.99). (Table 1)

Table 1: Analysis of the methodological quality of included studies

Study	Adequately randomised	Hidden allocation	Similar baseline	Blinded subject	Blinded researcher	Prevention of selective reporting	Similar outcome	Patients in compliance	Acceptable response rate	Similar time	Analysis of intention to treat	Quality
Robinson-Norris & Roberts (2017)	Yes	Yes	Yes	Yes	No	Yes	Yes	Yes	Yes	Yes	No	High
Yoon et al (2016)	Yes	Yes	Yes	No	Yes	Yes	Yes	Yes	Yes	Yes	No	High
Quinn et al (2007)	Yes	Yes	Yes	Yes	No	Yes	Yes	Yes	Yes	Yes	No	High
Tsutsi et al (2006)	Yes	Yes	Yes	Yes	No	Yes	Yes	Yes	Yes	Yes	No	High

Regarding the analysis of the results presented, the main measures used were the Measurements of Range of Motion (ROM) and the Visual Analogue Score (VAS). The other measures used were Constant Score (CS), followed by the Simple Shoulder Score (SSS), Oxford Shoulder Score (OSS), English version for the United Kingdom Questionnaire (EQ-5D and Shoulder Pain and Disability Index (SPADI). The follow-up ranged from 6 weeks to 1 year. (Table 2)

Table 2: Characteristics of included studies

The results were tabulated and dichotomised individually and the quantitative data was analysed statistically using Graphpad Prism 6.0. The inconsistency of the statistical data was analysed using the chi-square test to determine the heterogeneity. The I2 values of 75%, 50% and 25% were considered as high, average and low heterogeneity.

DISCUSSION

Robinson, Norris and Roberts (2017) demonstrated in their study with 41 patients submitted to hydraulic distension, in order to analyse whether the indication of physiotherapy associated with the guided domestic physical activity after the procedure interferes with the clinical outcome. The index presented in OSS, VAS and EQ-5D was significantly better in the analysis performed 4 weeks after the procedure in both groups.¹

In their study with 86 patients, Yoon et al. (2017) analysed the superiority of the treatment of Frozen Shoulder Syndrome with HD when compared to subacromial and intra-articular corticosteroid treatment, finding results that support the idea that HD presents better outcomes in the analysis of range of motion, predominantly in anterior flexion and external rotation of the shoulder and in VAS after 1 month with maintenance of comparative superiority after 3 months of follow-up. However, after 6 months of follow-up, the patients of all groups presented similar results on the pain and functional impairment scales.²

Quairish et al. (2007) performed a comparative study in order to evaluate the functional clinical improvement of patients submitted to HD and manipulation under anaesthesia, finding results favourable to HD, in addition to stressing the additional risks and costs involved in surgical manipulation.³ Tveita et al. (2008) evaluated the impact of corticosteroid treatment in this group of patients, by means of a clinical trial with 76 subjects, 39 of whom were submitted to corticosteroid treatment combined with HD and 37 to corticosteroid treatment alone, followed by 6 weeks, with no difference between the two groups being found.⁴

distension and after said procedure. Only Quairishi et al. (2007) presented a reduced follow-up analysis, in contrast to the other studies evaluated that had a follow-up time of up to 1 year after the procedure. Although all four studies included additional treatment methods to that in the focus of the meta-analysis, such as: physical therapy¹, Corticosteroid treatment^{2,4} and handling under anaesthesia³, the absolute values before and after the procedure are similar. However, due to the reduced sample and the difference in the follow-up period between the studies, the heterogeneity analysis with the two-sided chi-square test showed a p=0.81 index, preventing the extrapolation of the data.

The absence of the control group in all included studies prevented the determination of the actual efficacy and/or superiority of the hydraulic distension over the other methods used.

Therefore, greater efforts are needed in the research and application of randomised controlled clinical trials that can define the most effective therapeutic measures in the treatment of this pathology.

REFERENCES

- 1 Robinson PM, Norris J, Roberts CP. Randomized controlled trial of supervised physiotherapy versus a home exercise program after hydrodilatation for the management of primary frozen shoulder. *J Shoulder Elbow Surg.* 2017
- 2 Yoon et al. Intra-articular injection, subacromial injection, and hydrodilatation for primary frozen shoulder: a randomized clinical trial. *J Shoulder Elbow Surg.* 2016
- 3 Quairishi et al. Thawing the frozen shoulder: a randomized trial comparing manipulation under anaesthesia with hydrodilatation. *J Bone Joint Surg.* 2007
- 4 Tveita et al. Hydrodilatation, corticosteroids and adhesive capsulitis: A randomized controlled trial. *BMC Musculoskeletal Disorders.* 2008.
- 5 Sinha et al. Analysis of hydrodilatation as part of a combined service for stiff shoulder. *Shoulder & Elbow.* 2017
- 6 Yoong et al. Targeted ultrasound-guided hydrodilatation via the rotator interval for adhesive capsulitis. *Skeletal Radiol.* 2014.
- 7 Trehan et al. Is it worthwhile to offer repeat hydrodilatation for frozen shoulder after 6 weeks? *Int J Clin Pract.* 2010
- 8 Shaffer B, Tibone JE, Kerlan RK. Frozen shoulder A long-term follow-up. *J Bone Joint Surg Am.* 1992
- 9 Neviasser JS. Adhesive capsulitis of the shoulder: a study of the pathological findings in periartthritis of the shoulder. *J Bone Joint Surg* 1945
- 10 Reeves B. The natural history of the frozen shoulder syndrome. *Scand J Rheumatol* 1975.
- 11 Bulgen DY, Hazleman BL, Voak D. HLA-B27 and frozen shoulder. *Lancet.* 1976.
- 12 Andren L, Lundberg B. Treatment of rigid shoulders by joint distension during arthrography. *Acta Orthop Scand.* 1965.
- 13 Moher D, Cook DJ, Eastwood S, et al. Improving the quality of reports of meta-analyses of randomized controlled trials: the QUOROM statement. *Lancet.* 1999.
- 14 Lech G, Sudbrack G, Net CV. Adhesive capsulitis (frozen shoulder): a multidisciplinary approach. *Rev Bras Ortop.* 1993.
- 15 Filho AAF. Adhesive capsulitis. *Rev Bras Ortop.* 2005.

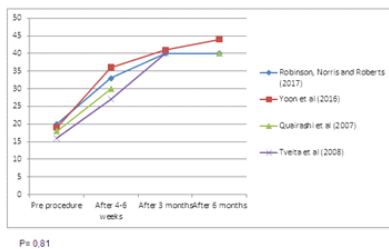


Figure 2: Comparative analysis of clinical outcomes in relation to range of motion to passive external rotation

CONCLUSION

Because of the limited number of validated clinical trials and the varying outcomes of follow-up, it was impossible to analyse the influence of other clinically relevant factors, such as the severity of local pain prior to the procedure, the use of additional medications, and the volume of fluid used in the hydraulic distension procedure, as well as to define the existence of superiority of the procedure in relation to the other existing treatment methods.

Regarding the parametric data analysed in all of the studies included, we can observe the distribution of the Range of Motion recovery average of passive external rotation prior to the hydraulic