

## Oncology

**KEYWORDS:** RPLND,  
ovarian cancer, CT

**CLINICOPATHOLOGICAL CORRELATION OF CT  
AND HISTOPATHOLOGY OF  
RETROPERITONEAL LYMPH NODE DISSECTION  
FOR CARCINOMA OVARY PATIENTS:A SINGLE  
CENTER RETROSPECTIVE STUDY**



Volume-4, Issue-9, September - 2019

ISSN (O): 2618-0774 | ISSN (P): 2618-0766

**Dr. Ahmed Pervez**

Assistant Professor, General Surgery, Department Of General Surgery, Sri Ramachandra Medical University, Chennai, Tamil Nadu, India – 600116

**Dr. Naveen Thimiri Mallikarjun\***

Post Graduate, General surgery, Department Of General Surgery, Sri Ramachandra Medical University, Chennai, Tamil Nadu, India – 600116 \*Corresponding Author  
tm.nav92@gmail.com

**Dr. Asha Reddy**

Senior Resident, General Surgery, Department Of General Surgery, Sri Ramachandra Medical University, Chennai, Tamil Nadu, India – 600116

**Dr. Cunnigaiper Dhanasekar Narayanan**

Professor, General surgery, Department Of General Surgery, Sri Ramachandra Medical University, Chennai, Tamil Nadu, India – 600116

**Article History**

Received: 06.02.2019

Accepted: 30.04.2019

Published: 10.09.2019

**ABSTRACT:**

**BACKGROUND:** Ovarian cancer account for a large portion of female genital cancer and most of these ovarian cancers are now detected in the early stages. Importance is now placed on less radical surgeries and the exact role of RPLNDs is yet to be defined. The aim of the study is to analyse the clinicopathological status of patients who underwent retroperitoneal lymphnode dissection(RPLND) for carcinoma ovary and to compare the size of the node on imaging (CT abdomen) with node positivity on HPE. This is the first such study correlating CT findings of lymph node with pathological lympho-vascular invasion in RPLNDs done for carcinoma ovary from India verified by literature search on pubmed and NCBI.

**METHODS:** A retrospective study of all patients who underwent RPLND diagnosed with ovarian cancer in our hospital over a period of 5 years (2011-15) were analysed. Various histopathological patterns were also evaluated.

**RESULTS:** Forty one patients diagnosed with ovarian cancer who underwent RPLND were evaluated. The average age of the study population was 49 years. The average tumor size was 9 cm. On analysis of para-aortic node size on imaging (CT abdomen) with node positivity on HPE, a size criterion of 14mm or more was associated with node positivity. On analysis of correlation between size of the tumor and size of para-aortic node to para-aortic node positivity on HPE were both insignificant. There is correlation between size of the tumor to lymphovascular invasion on HPE.

**CONCLUSION:** This study shows that the primary tumor size and para-aortic lymph node size can predict or suggest lymphovascular invasion and a para-aortic node size criterion of 14mm or more on CT can predict node positivity.

**INTRODUCTION:**

Ovarian neoplasm encompass tumors with various histologic patterns and different biologic behaviours. They grow rapidly and are predominately unilateral (Gershenson, 2007). The cure rates are relatively high; and the focus of surgery is now on fertility preservation while obtaining negative margins. Importance has been placed on early diagnosis to minimize radical surgery. Comprehensive staging in ovarian cancer comprises of peritoneal cytology, inspection and palpation of abdominopelvic contents,

lymph node dissection, omentectomy, and peritoneal biopsies along with removal of any suspicious lesion (ACOG, 2002).

The surgical approach for patients with a clinical stage I OGCT includes unilateral salpingo-oophorectomy with surgical staging (Kurman and Norris, 1977; Peccatori et al, 1995; Gershenson, 2007). The debate for the role of lymphadenectomy continues; however, many studies show no cases of nodal metastasis in patients with clinical stage I mucinous tumour of the ovary, negating the need for a lymphadenectomy (Schmeler et al, 2010)

Lymphadenectomy is still an integral part of surgical staging and treatment for later stages of ovarian cancers and also has an important role in both staging and retroperitoneal debulking.

**AIM:**

To perform a clinic-pathological analysis of retroperitoneal lymph node dissection performed for carcinoma ovary in a multi-specialty tertiary care centre in Chennai, India over a period of 5 years and to compare the size of the node on imaging (CT abdomen) with node positivity on HPE. The analysis includes various factors such as relationship of presence of lymphovascular invasion to lymph node positivity, relationship of size of para-aortic node to histopathological examination, size of primary tumor and the histological nature of the tumor.

**METHODS:**

A retrospective study was performed analyzing patients who underwent RPLND for carcinoma ovary between 2011 and 2015. All patients suspected to have carcinoma ovary on clinical examination underwent a transvaginal ultrasound and were tested for tumor marker CA125. A preoperative CT whole abdomen was also performed and the presence and size of the para-aortic nodes were recorded. Once the diagnosis was confirmed, patients were planned for retroperitoneal lymph node dissection (RPLND) and the same was done in conjunction with the gynecologists, who performed a salpingo-oophorectomy with the addition of a hysterectomy when indicated. Postoperative biopsy reports were reviewed and the pathological assessment of the primary tumour and para-aortic nodes were analysed. Adjunctive treatment was given based on the stage of the tumour.

**PATIENTS AND RESULTS:**

**Eligibility:** Any patients with histologically proven ovarian carcinoma were eligible for the study. Previous chemotherapy or

radiotherapy treatment eliminated patients from the study. Informed consent was obtained from all patients.

**Surgery:** Retroperitoneal lymph-node dissection with oophorectomy.

**RESULTS OF STATISTICAL ANALYSIS:**

A total of 41 women was diagnosed with ovarian cancer in the 5-year study period. The average age of the population was 49 years and the average tumor size was 9 cm.

**Analysis of the histologic pattern:**

On analysis of the pathological report diagnosed with ovarian malignancy, 66% were papillary serous carcinoma (27 patients), 12% were GCT (5 patients), 10% were mucinous (4 patients) and others were 12% (1 patient with borderline mucinous, 1 patient with endometrioid, 1 patient with mixed type and 1 patient with teratoma with squamous cell carcinoma).

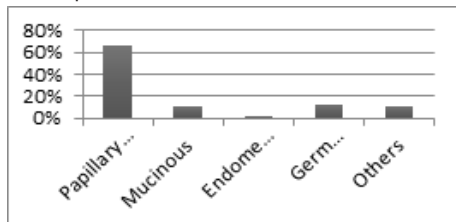


Figure 1

**Analysis of tumour size and para-aortic node size to node positivity on HPE:**

On analysis of all patients who underwent RPLND for ovarian malignancy, 7 patients (17%) had positive para-aortic nodes and 4 patients (10%) had other nodes that were positive. Among the patients who had other nodes positive, also had positive paraaortic nodes. There were no patients who had other nodes positive without a positive paraaortic node. The average size of the para-aortic node among node positive patients was 2.6 cm and whereas the average size of the para-aortic node among node negative patients was 1.7cm. A statistical analysis of the correlation of size of tumour and size of para-aortic node to para-aortic node positivity were both insignificant with a p value of .27 and .55 respectively.

**Mann-Whitney Test Ranks**

Table 1

	Tumor size	Node size
Mann-Whitney U	74.500	88.500
Wilcoxon W	95.500	718.500
Asymp. Sig. (2-tailed)		
Exact Sig. [2*(1-tailed Sig.)]	-1.133 .257	-.668 .504
	.268 <sup>b</sup>	.552 <sup>b</sup>

**Group Statistics**

Table 2

Para-aortic node positivity		N	Mean Rank	Ranks
Size of tumour	No	35	21.87	765.50
	Yes	6		
	Total	41	15.92	95.50
Size of node	No	35	20.53	718.50
	Yes	6		
	Total	41	23.75	142.50

**Test Statistics<sup>a</sup>**

Table 3

Para-aortic node positivity	N	Mean	Std. Deviation	Std. Error Mean
Size of tumour	No	35	9.51	5.249
	Yes	6	6.33	1.751
Size of node	No	35	1.74	.919
	Yes	6	2.83	3.061

**Analysis of lympho-vascular invasion with tumor size and para-aortic node positivity:**

On analysis of lympho-vascular invasion among 41 patients with proven ovarian malignancy, 29% patients had lympho-vascular invasion on histopathological examination (12 patients). A statistical correlation between presence of lympho-vascular invasion to size of the tumor and para-aortic node positivity was significant with p value of .006. Presence of lympho-vascular invasion can suggest paraaortic node involvement suggesting poor prognosis.

**Mann-Whitney Test Ranks**

Table 4

Lymphovascular invasion positivity		N	Mean Rank	Sum of Ranks
Size of tumour	No	29	24.28	704.00
	Yes	12	13.08	157.00
	Total	41		
Size of node	No	29	20.60	597.50
	Yes	12	21.96	263.50
	Total	41		

**Group Statistics**

Table 5

Lymphovascular invasion positive	N	Mean	Std. Deviation	Std. Error Mean
Size of tumour	No	29	10.41	5.308
	Yes	12	5.75	1.658
Size of node	No	29	1.76	.951
	Yes	12	2.25	2.221

**Test Statistics<sup>a</sup>**

Table 6

	Size of tumour	Size of node
Mann-Whitney U	79.000	162.500
Wilcoxon W	157.000	597.500
Z	-2.741	-.361
Asymp. Sig. (2-tailed)	.006	.718
Exact Sig. [2*(1-tailed Sig.)]	.006b	.745b

a. Grouping variable: Lymphovascular invasion positivity  
b. Not corrected for ties

**Analysis of size of para-aortic node on CT with node positivity on HPE:**

On analysis of size of para-aortic node on CT images of patients who underwent RPLND for ovarian malignancy with node positivity, 26% (11 patients) had a positive paraaortic node on CT. Among 11 patients with positive node on CT, 82% (9 patients) with node size of 14mm or more were positive on histo-pathological examination and 18% (2 patients) with node size less than 14mm were negative on histo-pathological examination. A size criterion of 14mm or more was highly suggestive of node positivity on HPE. It was also noted that patients who had no node enlargement on CT, also had no para-aortic node positivity on HPE.

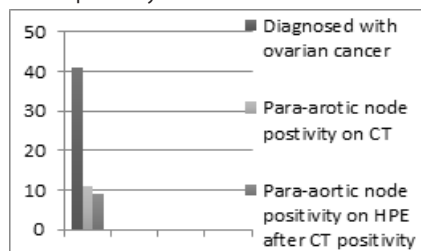


Figure 2

**CONCLUSION:**

One of the factors that affect the prognosis and the decision to give adjuvant treatment for a patient with ovarian malignancy is lymphovascular invasion. This study shows that the size of the

primary tumour and size of para-aortic lymph node can predict lymphovascular invasion. A larger study can help define the exact numerical cut-off for this correlation and the presence of para-aortic node on CT alone is not enough to ascertain the stage of patient. It depends on primary tumour size, tumour grade, lymphovascular invasion determined after an adequate retroperitoneal lymph node dissection. A size criterion of 14mm or more on CT can suggest FIGO stage 3 ovarian carcinoma.

#### DISCUSSION:

Ovarian malignancy is a lethal genital malignancy [1]. Only one third of cases are diagnosed in the early stages of the disease. Lymphatic node metastasis results in a change from stage I to stage III. 5-year survival decreases from more than 90% to 20% - 60% if there is presence of lymph node metastasis and adjuvant therapy is needed [2-4]. However, there is debate on the extent of lymphadenectomy, particularly in early staged unilateral tumors (confined to only one ovary) [5,6]. Despite a detailed history of lymphadenectomies in scientific literature, there are only a limited number of reports analyzing this topic [5-7]. Furthermore, they are all of a retrospective nature and only include a small number of patients. The staging procedures of these studies and the extent of lymphadenectomies performed are also debatable. The prevalence of lymph node involvement depends closely on the stage of the disease and the number of lymph nodes removed and examined (1). This is the first such study correlating CT findings of lymph node with pathological lympho-vascular invasion in RPLNDs done for carcinoma ovary from India verified by literature search on pubmed and NCBI.

#### REFERENCES:

1. Randomised study of systematic lymphadenectomy in patients with epithelial ovarian cancer macroscopically confined to the pelvis A Maggioni, P Benedetti Panici, T Dell'Anna, F Landoni, A Lissoni, A Pellegrino, R S Rossi, S Chiari, E Campagnutta, S Greggi, R Angioli, N Manci, M Calcagno, G Scambia, R Fossati, I Floriani, V Torri, R Grassi and C Mangioni *Br J Cancer* 95: 699-704; advance online publication, August 29, 2006; doi:10.1038/sj.bjc.6603323
2. Lymph node metastasis in grossly apparent clinical stage Ia epithelial ovarian cancer: Hacettepe experience and review of literature Guldeniz Aksan Desteli1\*, Murat Gultekin2 , Alp Usubutun3 , Kunter Yuce4 , Ali Ayhan1. *World Journal of Surgical Oncology* 2010, 8:106 <http://www.wjso.com/content/8/1/106>
3. Analysis of para-aortic lymphadenectomy up to the level of the renal vessels in apparent early-stage ovarian cancer Suk-Joon Chang1 , Robert E. Bristow2 , Hee-Sug Ryu1 *J Gynecol Oncol* Vol. 24, No. 1:29-36
4. Prognostic impact of lymphadenectomy in clinically early stage malignant germ cell tumour of the ovary H Mahdi, R E Swensen, R Hanna, S Kumar, R Ali-Fehmi, A Semaan, H Tamimi, R T Morris and A R Munkarah *Br J Cancer* 105: 493-497; advance online publication, July 19, 2011; doi:10.1038/bjc.2011.267