

## Gynecology

**KEYWORDS:** encephalitis,  
NMDA, teratoma, ovary

**ANTI-NMDA RECEPTOR ENCEPHALITIS: 2  
CASE REPORTS ASSOCIATED WITH  
OVARIAN TERATOMA AND A LITERATURE  
REVIEW**



Volume-2, Issue-10, October - 2017

**Sancho-Saúco J\***

PhD, Department of Obstetrics and Gynecology, University of Alcalá, Ramón y Cajal University Hospital, Madrid, Spain. Electronic\*Corresponding Author  
jsanchosauco@gmail.com

**Corraliza-Galán V**

Department of Obstetrics and Gynecology, University of Alcalá, Ramón y Cajal University Hospital, Madrid, Spain.

**Lázaro-Carrasco de la Fuente J**

Department of Obstetrics and Gynecology, University of Alcalá, Ramón y Cajal University Hospital, Madrid, Spain.

**Sánchez-Martínez C**

PhD, Department of Obstetrics and Gynecology, University of Alcalá, Ramón y Cajal University Hospital, Madrid, Spain.

**Pelayo-Delgado I**

PhD, Department of Obstetrics and Gynecology, University of Alcalá, Ramón y Cajal University Hospital, Madrid, Spain.

**De Pablos-Antona MJ**

Department of Obstetrics and Gynecology, University of Alcalá, Ramón y Cajal University Hospital, Madrid, Spain.

**Cabezas-López E**

Department of Obstetrics and Gynecology, University of Alcalá, Ramón y Cajal University Hospital, Madrid, Spain.

**García-Pérez JC**

PhD, Department of General and Gastrointestinal Surgery, University of Alcalá, Ramón y Cajal University Hospital, Madrid, Spain

**Article History**

Received: 12.08.2017

Accepted: 19.09.2017

Published: 10.10.2017

**ABSTRACT:**

Receptor N-methyl-D-aspartate (NMDA) antibodies have been associated with a paraneoplastic syndrome associated with ovarian tumors (teratomas) mainly in young women. Its typical clinical picture is presented as neuropsychiatric symptoms. The clinic is sometimes confusing and diagnostic tests sometimes do not allow us to do a good differential diagnosis. These patients benefit from early diagnosis and removal of teratoma, hence the importance of a thorough gynecological evaluation if there was a suspicion of this disease. However the absence of teratoma not rule us the presence of this syndrome. We are going to present two cases with this syndrome that they were diagnosed differently and they had an opposite outcome. Both cases have in common the presence of teratoma and in both of them, the work of the gynecologist was essential for the diagnosis of ovarian tumor and therefore to establish the etiology of encephalitis.

**INTRODUCTION**

The presence of N-methyl-D-aspartate (NMDA) receptor antibodies has recently been associated with a paraneoplastic syndrome in young women with ovarian cysts<sup>1,2</sup>.

It is an antibody-mediated autoimmune encephalitis presenting as clinical picture of typical neurological symptoms (such as decreased level of consciousness, involuntary abnormal movements, autonomic nervous system dysregulation and seizures) but also psychiatric symptoms (such as personality changes, hallucinations, aggressive behaviour or catatonic-like episodes) and even episodes of hyperthermia and respiratory failure. These symptoms are often preceded by a flu-like syndrome. The severity of symptoms varies:

there are patients with few symptoms and other patients with rapid evolution dramatic cases requiring admission to intensive care for many months.

Firstly in 2005, this syndrome was reported in 4 patients with ovarian teratomas. During the following 3 years, 400 cases (not all of them associated with tumor) were described in the literature. So the prevalence of the disease seems underestimated, although it is presented more often than other paraneoplastic encephalitis<sup>1,3</sup>.

Most patients affected are women (about 80-90% 3,4), young (mean age 23 years and increasingly diagnosed in children and teenagers 4) and some ethnic groups (black and asian people 3,5). Furthermore, it has been suggested that some risk factors as vaccine administration, systemic infections, autoimmune diseases (myasthenia gravis, Lambert-Eaton syndrome) or genetic factors (microdeletion in the short arm of chromosome 6) can act as an adjuvant of the autoimmune response 3. There is clear evidence of association with ovarian teratoma (one or both ovaries) and it is the most frequent etiology (in approximately 50% of women, especially older 4). Approximately 3% of teratomas are malignant, but this number increases to 50-60% in teratomas associated with paraneoplastic syndrome 6. Other sources of neoplasia (including breast, lung, thymus, testis, pancreas, neuroblastoma or Hodgkin lymphoma) are much less common than teratoma and mainly older than 45 years old 3,5. However, in some patients, no teratoma or other tumours can be found. In most cases, the neurological and psychiatric symptoms preceded the tumor diagnosis<sup>6,7</sup>.

Tumor resection appeared important to prevent long-term neurologic sequelae. The surgery performed early is often associated with favorable outcome (even with complete final recovery) and it is still effective 1 year after diagnosis of severe encephalitis. However in some cases, the patients may require intensive care for months 1. Therefore, a young woman showing encephalitis of unknown etiology should consult a gynecologist to

rule out ovarian pathology. Although none of the diagnostic work-up (including exploratory laparoscopy) showed the presence of an ovarian teratoma, it could exist<sup>8</sup>.

We are going to talk about 2 patients with anti-NMDA receptor encephalitis and we are going to emphasize the importance of early action gynecologists. This encephalitis is a rare complication of an ovarian teratoma, but it is very important its research, diagnosis and treatment.

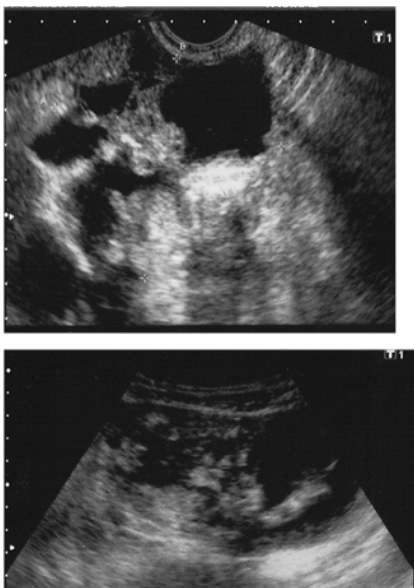
**CASES PRESENTATION**

**First case:**

Patient 1 was 27 years-old Paraguayan women, no previous pregnancy and without illness. This patient went to the Emergency Department of our hospital because she suffered an episode of loss of consciousness and generalized tonic-clonic seizures with postictal stupor. In the Emergency Department, she presented another episode of similar characteristics. The patient denied fever and infectious symptoms the previous days and she didn't have any symptoms to suspect the presence of adnexal tumor. Firstly, an electroencephalogram (EEG) was performed and it showed a rapid cerebral bioelectrical activity of small amplitude. A magnetic resonance imaging (MRI) was also done but without brain findings. The patient was diagnosed with generalized seizures episode and she was treated with levetiracetam.

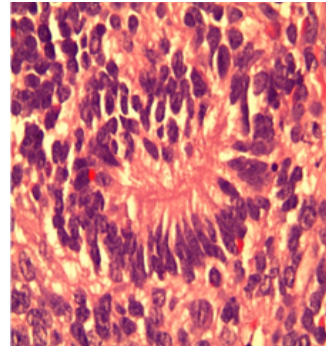
Next day, she went back to the Emergency Department because she presented sensory deficits in the left hand; computed tomography (CT) scan was performed without showing pathological findings. Later, she showed generalized tonic-clonic seizures in the lower limbs and left upper limb, inappropriate speech, and finally encephalopathy with status epilepticus. A lumbar puncture (which shows pleocytosis with normal glucose and proteins in cerebrospinal fluid (CSF)) and a new EEG (which already shows slow and low amplitude) were performed. So, she was admitted to neurology department.

During patient's admission to hospital, she has low level of awareness and desaturation. So, she needs to be admitted to the Intensive Care Unit (ICU). There, an abdominal mass is superficially palpable in the right iliac fossa. A gynecologist is alerted and a transvaginal ultrasound is performed. It reports a 10-12 cm abdominal mass with similar characteristics to ovarian teratoma (Figures 1A y 1B). Serum tumor markers are requested: CA 125 and alpha-fetoprotein are increased.

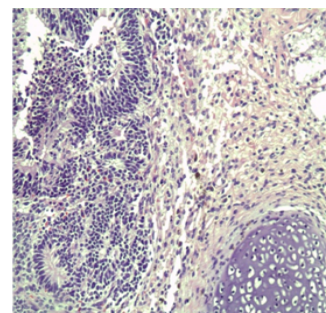


**Figura 1A & 1B** Ultrasound image of great adnexal tumor corresponding ovarian teratoma.

The patient is diagnosed of anti-NMDA receptor encephalitis associated with ovarian teratoma. An emergency laparotomy is performed. Intraoperative biopsy reports the presence of teratoma so we remove right fallopian tube and ovary. The presence of anti-NMDA antibodies in CSF is confirmed. The patient is treated with intravenous immunoglobulin, corticosteroids, cyclophosphamide and rituximab. The pathologist reports immature neuroepithelial (neuroepithelial rosettes) (Figure 2) and immature mesenchymal tissue (cartilage and fat) (Figure 3) with large areas of necrosis. The diagnosis is high-grade immature ovarian teratoma (FIGO stage IA). So, the treatments are suspended and systemic chemotherapy begins with bleomycin, cisplatin and etoposide (4 cycles).



**Figura 2.** Neuroectodermal rosette



**Figura 3.** Immature neuroectodermal tissue and cartilage.

After surgery, the patient's evolution is satisfactory response. She presents marked improvement in neurological symptoms, so she goes home two months after admission. Nowadays, she can speak and walk correctly. On the explorations carried out subsequently, (including positron emission tomography (PET) / CT), tumor residual disease don't have been showed up. She has regular reviews in the neurology, oncology and gynecology department.

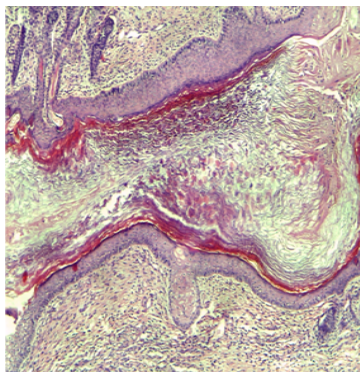
**Second case:**

Patient 2 is 33 years-old Spanish women, without illness (only seizures in childhood, self-limiting and no treatment required) and a vaginal delivery 5 months ago. This patient goes to Emergency Department of our hospital because she suffers symptoms including high fever (38,5 °C), generalized headache and behaviour changes for 3 days. In the Emergency Department, she presents with a decreased level of consciousness and sleepiness. Suddenly, she presents with a generalized tonic seizure that lasted 5 minutes and an important postictal period. So, she needs to be admitted to the ICU. Cranial CT scan (not relevant findings) and lumbar puncture (clear cerebrospinal fluid with leucocytosis, lymphocytosis and elevated levels of proteins, suggestive of a viral etiology) was performed. Analytical is also performed and shows leucocytosis and elevated C-Reactive Protein (CRP), but not clear focal infection. Empirical treatment is started and the patient is treated with acyclovir, cefotaxime, vancomycin, phenytoin and dexamethasone. During patient's admission to ICU, she improves but she presents persistent raised temperature with little fluctuation, disorientation, emotional lability, anterograde amnesia and not hemodynamic compromise.

Five days later, she is admitted to Infectious Diseases department. Complementary studies are performed and they show a normal ECG and thyroid profile. CSF analysis and serologic tests result negative. Therefore, the patient is diagnosed of meningoencephalitis of unknown etiology, and infection is apparently not the cause.

MRI is performed and it shows focus limbic encephalitis in the left temporal lobe. But the patient has a progressive level of consciousness deteriorates and fever. Lumbar puncture is repeated. Parenteral immunoglobulins and corticosteroids are again started. Because of decreased level of consciousness, the patient is readmitted to ICU. EEG is performed (it reports as non-convulsive status) and video-EEG that shows moderate to severe encephalopathy without crisis. Gynecologic transvaginal ultrasound is performed and there is no evidence of ovarian or adnexal pathology. The patient is intubated and sedated and she presents spasticity and clonus in lower limbs.

Six days later, we know that antiNMDA antibodies are positive and serum tumor makers are negative. The patient is diagnosed of autoimmune anti-NMDA receptor encephalitis and it is started therapeutic regimen of rituximab and cyclophosphamide. However, despite treatment, the evolution is slow and torpid. So, we research possible germ cell tumor. Pelvic MRI is performed and it is informed as nonspecific, with dominant lesion of 15 mm and parietal calcification in right ovary. Transvaginal ultrasound is repeated after 1 month of admission and it reports an image in right ovarian, with similar characteristics to teratoma. Laparoscopic right salpingo-oophorectomy is performed and the pathologist confirms existence of mature cystic teratoma without immature components inside (Figure 4). No macroscopic changes are observed in left ovary.



**Figure 4. Cysti Formation covered by hairy skin and dermal appendages**

24 hours after surgery, there are changes in EEG with disappearance of status state. Sedation is decreased and there is not recurrence of crisis in EEG. Dyskinesias persist so it is decided to start plasmapheresis. The patient presents voluntary movements but also dyskinesias and dystonic movements. EEG shows that encephalopathy persists and crises appear so she precises deep sedation again. One month later after surgery, antiNMDA determination is performed in serum and cerebrospinal fluid and they remain positives. No evidence of injury in the left ovary is showed in ultrasound or pelvic MRI. However, because of long and slow evolution, intensivists propose left salpingo-ooforectomy. Department of Gynecology refuse it. Nowadays, the patient remains hospitalized in ICU.

## CONCLUSIONS

Ovarian teratoma is one of the most common ovarian tumours in young women 1,6,9. It represents approximately 10-20% of the total ovarian mass in this age group 9. Anti-NMDA receptor encephalitis has been associated with ovarian teratomas (both mature and immature<sup>1,9,10,11</sup>).

In the 90s and early 2000s in Japan, it was described some cases of

unknown etiology encephalitis. The first 2 cases of encephalitis reported in the literature in young women with ovarian tumors dating from 1997 12, but it was not until 2007 when Dalmau described a new neuropsychiatric syndrome, which he called "encephalitis associated with antibodies against NMDA receptors" or "NMDA antireceptor encephalitis" 1. Subsequently, it has been emphasized that the neural components in the ovarian teratoma can act as a producer of antiNMDA antibodies. However, in some of these patients has not been able to demonstrate the presence of ovarian teratoma<sup>13</sup>.

NMDA receptors are ligand-gated cation channels with important roles in synaptic transmission and plasticity. They are expressed in the hippocampus and in the front area of the brain which are involved in memory and learning 2,14. These receptors have three subunits: NR1 and NR2 and a secondary that is NR3 13. Dalmau's laboratory investigations showed that pathogenic antibodies were generated against the NR1 subunit 1. It is speculated that ectopic expression of the NR1 subunit causes faulty immune tolerance or disease pseudoviral and it can unchain an abnormal immune response 1,6,15. It has been found that ovarian teratomas have antigenic neural tissue with formation of antibodies that cross-react with NMDA receptors in the hippocampus<sup>16</sup>.

The incidence of this new entity is unknown. The first 12 cases were described by Dalmau in 2007 1, and in 2008 he published clinical and laboratory features in a series of 100 patients 2. In the following year that number reached 300. The same year, Florance et al. reported a series of 81 patients 17 and nowadays it is reported cases like ours. This dramatic increase suggests that this disease is more common than previously suspected and probably insufficiently recognized.

Generally, clinical symptoms show a progression. It was described by Iizuka et al 3,9,10, and they are classified into 5 phases.

- 1) Prodrromal phase: It is suffered about 70% of patients and it is a flu-like syndrome. After a mean period of two weeks it is followed by a psychotic behaviour, so many of them are seen by psychiatrists initially.
- 2) Psychotic phase: The patients have emotional disorders, anxiety, insomnia, mania, paranoia, cognitive decline and schizophrenia-like symptoms.
- 3) Unresponsive phase: It usually comes from echolalia to mute, akinetic state and resembling catatonia (up to 85% of patients may be comatose).
- 4) Hyperkinetic phase: it includes complex involuntary movements, tachycardia, hypertension, hyperthermia, hypersalivation and convulsions with hypoventilation (up to 65% of cases) that may require respiratory support and ICU admission (up to 77%)<sup>4,5,9,10</sup>
- 5) Final stage: a gradual improvement occurs in months and it may get a full recovery in three years or more. Patients without teratoma may have episodes of unconsciousness and confusion of longer duration or worse outcome than those with teratoma<sup>3</sup>.

It has been reported less than 5% of patients with monosymptomatic syndrome, and it can cause confusion 3,18. Neurological symptoms such as movement disorders and atypical symptoms (cerebellar ataxia, hemiparesis) are more common in adolescents whereas psychiatric symptoms, memory deficits and central hypoventilation occur most common in adults. However in most cases it is presented as a mixture of neurological and psychiatric symptoms<sup>2</sup>.

In our first case, the patient does not have a prodromal phase but it can be seen a psychotic phase, hence that incomprehensible and



irresponsible behaviour leak urgency, followed within a few days of a hyperkinetic phase including autonomic instability with respiratory failure which required ICU admission. However the second case presents a prodromal phase with headache and fever followed by a psychotic phase. Due to the history of birth five months earlier, it was initially mistaken for postpartum psychiatric disorders.

The diagnostic tools available for the diagnosis of this disease include:

- 1) Analysis in serum and CSF antibody against the NMDA receptor. Their positivity confirms the diagnosis. It has greater sensitivity in CSF than in serum (85% vs 100%)
- 2) EEG which often reveals slowly activity. It is important the video EEG for monitoring.
- 3) Analysis of CSF showing lymphocytic pleocytosis, elevated protein and oligoclonal bands. (60-80% of patients)
- 4) Brain MRI usually shows abnormal signs in mesotemporal region, although it may be nonspecific up to 50% of patients and show minimal changes in monitoring despite the severity of the symptoms<sup>2,3,4,5,19</sup>.

Moreover brain biopsy usually shows perivascular lymphocytic infiltrates, microglial activation and IgG deposits in the hippocampus, basal forebrain, basal ganglia and spinal cord but it does not give a diagnosis of anti-NMDA encephalitis<sup>3,20</sup>.

However, although these tests can initially be non specific, they can help rule out other diseases (infectious, metabolic, toxic... 4). But sometimes there are patients who presented positive results for infections due to the existence of concomitant infections (mycoplasma, herpes zoster...) and it can delay diagnosis 3. In addition, if we want to confirm the presence of tumor, we have to do more extensive studies as abdominopelvic and transvaginal ultrasound, abdominopelvic CT or MRI and blood tumor markers (Ca125, BHCG, AFP, testosterone) but they are negative in many patients<sup>3</sup>.

In the Dalmau series of 100 patients, 58 cases were diagnosed with a tumor, of which 53 were diagnosed with ovarian teratoma. In addition, we note that 57 of them had neurological symptoms before diagnosis of the tumor (3 weeks to 4 months before diagnosis of teratoma) 2,6,7,12. Hence the importance to alert the department of gynecology when anti-NMDA encephalitis antibodies suspected to be able to carry out a thorough gynecological evaluation and thus rule out the possibility of ovarian teratoma. Even some patients who undergo exploratory laparoscopy with oophorectomy showed the presence of ovarian teratomas. They also are available immunohistochemical tests that identify the expression of NR2B epitope in the cytoplasm of oocytes and it can prove the presence of immunohistochemical reactivity in patients with this type of encephalitis 13. It is also possible that in some patients, especially those who do not have teratoma, we note the presence of other positive autoantibodies (ANA, anti-TPO ...20). Even we found in the literature 3 cases reported in pregnant patients: 1 with bilateral teratomas that interrupted the pregnancy, and the other two who carried the pregnancy to term with healthy babies (one also with teratoma) 3. In our first patient, the diagnostic tests (except brain MRI that is normal) point to an encephalitis associated with NMDA receptor antibodies: presence of pleocytosis in CSF or slow activity on EEG. Suspecting limbic encephalitis antireceptor NMDA and awaiting confirmation of antibodies in CSF, an abdominal exploration reveals the presence of a hypogastric mass. So they notify the department of gynecology promptly. This attitude meant to make an early diagnosis of adnexal tumor support teratoma. In the second patient, the diagnosis was somewhat later (1 month after admission), because initially they suspected viral

etiology and showed some improvement after antibiotic treatment plan. In the vaginal ultrasound it was performed days after admission evidenced no any teratoma. However to eventual deterioration in income in the ICU and due to the presence of calcification in the right ovarian in the MRI, it was decided to track the presence of ovarian teratoma again with ultrasound.

In our two cases, the importance in the diagnosis promptly not only lies in the prognosis of encephalitis but in the teratoma, since the prognosis for these patients is dependent on the disease staging and tumor grade. One of our patients had a mature teratoma and other immature. The immature teratoma is a rare disease. Of all malignant ovarian tumors, only 5% relates to germ cell tumors, of which the immature teratoma represents less than 1%. It is usually unilateral and it is usually presents as a unilateral pelvic mass asymptomatic 21. As in mature teratomas, when associated with encephalitis most women have no gynecological pathology.

The vast majority of reported cases improved after tumor resection. Patients who received surgical treatment within the first four months of the onset of neurological symptoms showed the best prognosis for recovery 2. An interesting finding, highlighted by Iizuka et al, was that both the group of patients treated surgically and untreated by surgery showed similar improvement (84% vs. 71), although the patients that no tumor could be demonstrated evolved worse and died more frequently 3,9. The recommended surgical treatment in cases of benign tumors is removal of the tumor burden, either by cystectomy or oophorectomy, not yet clear in the literature which is the recommended setting 16. Asai et al suggest that both cystectomy and adnexectomy have the same neurological outcome after 2 years of follow-up 22. In cases of immature teratoma, with a median age at diagnosis of 20 years, fertility preservation is important in the treatment of these malignancies factor. Intraoperative biopsy helps proper staging of the tumor and to try to preserve fertility treatment. In patients with low-grade stage and it seems FIGO I enough performing surgical staging with unilateral oophorectomy because most tumors are confined to the ovary. One patient with tumor grade 2-3 or FIGO stage II-IV should receive additional treatment with adjuvant chemotherapy including bleomycin, etoposide and cisplatin. The current combination of chemotherapy has improved disease-free survival in > 95% and only a small percentage caused early menopause 17. The treatment received by our first patient is similar to that described, with great improvement in neurological symptoms and general condition. The second patient received an outline of cyclophosphamide and rituximab, although finally pathology showed a mature teratoma, no evidence of malignancy.

Other first-line treatment modalities include corticosteroids (to reduce inflammation), intravenous immunoglobulin and plasmapheresis, whose effectiveness and speed of action is greater in patients with resected tumor than women without tumor or without diagnosis, which usually need second-line treatments like rituximab, cyclophosphamide and azathioprine (with the aim of at least lessen the severity of the disease and has been associated as an additional factor of good prognosis in those who failed the first-line treatments and reduces relapse) 2,3,4,5,9,10,17,19. Patients treated with immunosuppressive therapy responded to treatment more slowly than those undergoing surgery 17. Many studies have emphasized the variability of response to treatment. In up to 80% of patients, tumor resection with 1st line immunotherapy treatments caused an improvement in days to weeks, while among those without tumor only 48% had a similar improvement 3. It is noteworthy that, once the clinical improvement, maintenance immunosuppressive treatment is not necessary 12. Our patients were treated with most of the treatments described with the intention of improving the clinical picture.

As for the prognosis, they have been documented with slow and incomplete recovery neuropsychiatric sequelae in up to 75% of cases (mean 7 months, but cases have been reported up to 3 years).

Recovery usually occurs in the reverse order in which the symptoms 3 and clinical improvement occurred often it correlates with decreased antiNMDA antibody titers in blood and CSF 23. Factors associated with a good prognosis are early treatment, with no need for ICU and the presence of some severe symptoms within the first four weeks 5. Up to 20-25% has relapses, especially in the first 2 years and sometimes associated with recurrences of ovarian teratoma. Relapses are usually less severe, more often monosymptomatic, with fewer readmissions in the ICU and are usually more common in patients without tumor initially 5. Deaths occur in up to 5-7% of patients (with an average of 3.5 months after the debut<sup>3,4,5</sup>).

In conclusion, the anti-NMDA encephalitis antibodies are an emerging disease that deserves full attention from neurologists, psychiatrists, gynecologists and intensivists. These patients benefit from early diagnosis and immediate treatment of teratoma, hence the importance of a thorough gynecological evaluation suspicion of this disease.

#### LIST OF ABBREVIATIONS

Receptor N-methyl-D-aspartate: NMDA  
Electroencephalogram: EEG  
Magnetic resonance imaging: MRI  
Computed tomography: CT  
Cerebrospinal fluid: CSF  
Intensive Care Unit: ICU  
Positron emission tomography: PET  
C-Reactive Protein: CRP

#### REFERENCES

- Dalmau J, Tüzün E, Wu H, Masjuan J, Rossi JE, Voloschin A, et al. Paraneoplastic anti-N-methyl-D-aspartate receptor encephalitis associated with ovarian teratoma. *Ann Neurol*. 2007; 61:25-36.
- Dalmau J, Gleichman AJ, Hughes EG, Rossi JE, Peng X, Lai M, et al. Anti-NMDA-receptor encephalitis: case series and analysis of the effects of antibodies. *Lancet Neurol*. 2008; 7:1091-8.
- Dalmau J, Lancaster E, Martinez-Hernandez E, Rosenfeld MR, Balice-Gordon R. Clinical experience and laboratory investigations in patients with anti-NMDAR encephalitis. *Lancet Neurol*. 2011; 10: 63-74.
- Tumbi A, Gilani A, Scarff JR, Kaur G, Lippmann S. Anti-N-methyl-D encephalitis. *Innov Clin Neurosci*. 2011; 8(9):24-5.
- Titulaer MJ, McCracken L, Gabilondo I, Armangué T, Glaser C, Iizuka T et al. Treatment and prognosis factors for long-term outcome in patients with antiNMDA receptor encephalitis: an observational cohort study. *Lancet Neurol*. 2013; 157-65.
- Vitaliani R, Mason W, Ances B, Zwerdling T, Jiang Z, Dalmau J. Paraneoplastic encephalitis, psychiatric symptoms, and hypoventilation in ovarian teratoma. *Ann Neurol*. 2005; 58: 594-604.
- Gultekin SH, Rosenfeld MR, Voltz R, Eichen J, Posner JB, Dalmau J. Paraneoplastic limbic encephalitis: neurological symptoms, immunological findings and tumour association in 50 patients. *Brain*. 2000; 123 (Pt 7): 1481-94.
- Boeck AL, Logemann F, Kraub T, Hussein K, Bultmann E, Trebst C et al. Ovarectomy despite negative imaging in anti-NMDA receptor encephalitis: effective even late. *Case Rep Neurol Med*. 2013; ID 843192. [Electronical Publication: 26 feb 2013.](http://www.caserep.com/abstract/843192)
- Iizuka T, Sakai F, Ide T, Monzen T, Yoshii S, Iigaya M, et al. Anti-NMDA receptor encephalitis in Japan: long term outcome without tumor removal. *Neurology*. 2008; 70:504-11.
- Iizuka T, Sakai F. [Anti-NMDA receptor encephalitis—clinical manifestations and pathophysiology]. *Brain Nerve*. 2008; 60: 1047-60.
- Tanyi JL, Marsh EB, Dalmau J, Chu CS. Reversible Paraneoplastic Encephalitis in Three Patients with Ovarian Neoplasms. *Acta Obstet Gynecol Scand*. 2012 May; 91(5):630-4.
- Revilla FJ, McMasters MD, KobetChA, Espay AJ. Encephalitis associated with NMDA receptor antibodies: recognizing a novel neuropsychiatric syndrome. *Rev Neuropsiquiatr*. 2010; 73: 20-25.
- Tachibana N, Kinoshita M, Saito Y, Ikeda S. Identification of the N-Methyl-D-Aspartate Receptor (NMDAR)- related epitope, NR2B, in the normal human ovary: implication for the pathogenesis of Anti-NMDAR encephalitis. *Tohoku J. Exp. Med*; 2013; 230, 13-6
- Waxman EA, Lynch DR. N-methyl-D-aspartate receptor subtypes: multiple roles in excitotoxicity and neurological disease. *Neuroscientist*. 2005, 11: 37-49.
- Anderson NE, Barber PA. Limbic encephalitis—a review. *J Clin Neurosci*. 2008; 15: 961-71.
- Sonn TS, Merritt DF. Anti-NMDA-receptor encephalitis: an adolescent with an ovarian teratoma. *J Pediatr Adolesc Gynecol*. 2010; 23:141-44.
- Florange NR, Davis RL, Lam C, Szperka C, Zhou L, Ahmad S, et al. Anti-N-methyl-D-aspartate receptor (NMDAR) encephalitis in children and adolescents. *Ann Neurol*. 2009; 66:11-8.
- Keller S, Roitman P, Ben-Hur T, Bonne O, Lotan A. Anti-NMDA receptor encephalitis presenting as an acute psychotic episode in a young woman: an underdiagnosed yet treatable disorder. *Case Rep Psychiatry*. 2014. ID 868325.
- Sabin TD, Jednacz JA, Staats PN. Case records of the Massachusetts General Hospital. Case 26-2008: A 26-year-old woman with headache and behavioral changes. *N Engl J Med*. 2008; 359: 842-53.
- Tüzün E, Zhou L, Baehring JM, Bannykh S, Rosenfeld MR, Dalmau J. Evidence for antibody-mediated pathogenesis in anti-NMDAR encephalitis associated with ovarian teratoma. *Acta Neuropathol*. 2009; 118(6): 73743.
- Gershenson DM. Management of ovarian germ cell tumors. *J Clin Oncol*. 2007; 25:

2938-43.

- Asai S, Ishimoto H, Yabuno A, Asada H, Seki M, Iwata S. Laparoscopic cystectomy of ovarian teratoma in anti-NMDAR encephalitis: 2 case reports. *J Minim Invasive Gynecol*. 2011; 18: 135-7.
- Leshner AP, Myers TJ, Tecklenburg F, Streck CJ. Anti-N-methyl-D-aspartate receptor encephalitis associated with an ovarian teratoma in an adolescent female. *J Pediatric Surg*. 2010; 45; 1550-53.