

Surgery

KEYWORDS: 3-D Printing,
Mandibular Fractures,
Stereolithography,

**APPLICATION OF VIRTUAL SURGICAL
PLANNING AND RAPID PROTOTYPING IN
MAXILLOFACIAL TRAUMA SURGERY: A CASE
SERIES**



Volume - 7, Issue - 1, January - 2022

ISSN (O): 2618-0774 | ISSN (P): 2618-0766

**Dr Nitish Chandra
Gupta***

Assistant professor (M.D.S) in Department of Oral and Maxillofacial surgery, Subharti Dental College, Swami Vivekanand Subharti University, Meerut, Uttar Pradesh.*Corresponding Author

**Dr Chitra
Chakravarthy**

Professor and H.O.D(M.D.S)Department of Oral and Maxillofacial Surgery, Navodaya Dental College, Raichur, Rajiv Gandhi University of Health Sciences, Karnataka.

Dr Shivraj Wadaragi

Professor (M.D.S) Department of Oral and Maxillofacial Surgery, Navodaya Dental College, Raichur, Rajiv Gandhi University of Health Sciences, Karnataka

Dr Ravi Patil

Professor (M.D.S) in Department of Oral and Maxillofacial Surgery, Navodaya Dental College, Raichur, Rajiv Gandhi University of Health Sciences, Karnataka..

INTERNATIONAL JOURNAL
OF PURE MEDICAL RESEARCH

**ABSTRACT**

Mandibular fractures are one of the most common traumatic injuries which require treatment from oral and maxillofacial surgeon. With the recent advancements in computer aided surgical planning and 3d printing technique have provided new tool for predictable management of maxillofacial trauma and reconstruction. Purpose of this study is to show various applications of virtual surgical planning and 3d printing in maxillofacial trauma surgery. Using patient's high resolution CT scan virtual surgical planning followed by mock surgery on 3d printed mandibular model was performed. Pre-adapted miniplates were used to accurately transfer preoperative plan intra-operatively. Use of virtual surgical planning and mock surgery on 3d printed model enabled us to accurately transfer preoperative plan intraoperatively using pre adapted miniplates. Duration of surgery was significantly reduced and complications of general anesthesia were minimal. Also, virtual surgical planning enables operator to formulate best possible treatment plan for the patient.

INTRODUCTION:

Mandibular fractures comprise some of the facial injuries corrected by a maxillofacial surgeon. Maxillofacial injuries are not only psychologically disturbing but also functionally debilitating to the patient^[1].

The mandible accounts for 15.5 to 59% of all fractures whereas pediatric mandibular fractures account for 32.7% of all facial fractures followed by nasal bone fractures and midface fractures [2]. With the advent of newer technologies, it has become easier to plan and execute procedures and also to anticipate complications [3]. The use of computer-based surgery is rapidly enhancing the surgical field in numerous disciplines including orthopedics, cardiothoracic surgery, maxillofacial surgery, ENT etc.

It even makes surgical navigation possible which helps not only in the diagnosis but also in the surgical planning of the case. The predictability of the surgical procedure improves with the use of technology and assists the surgeon in completing the procedure faster^[4].

Surgical navigation has been applied in maxillofacial surgery for the

management of complex midface fractures, complex orbital trauma reconstruction, skull base surgery, TMJ surgery etc.^[5].

3D printing is one such newer tool which also uses a digital imaging technology and converts it into printable models which can not only be used as educational models, for mock surgery and also to examine the unique anatomical variations as seen in each individual^[6].

Computer-aided design and manufacturing, intraoperative navigation, and intra-operative imaging have provided new tools to aid in the predictable treatment of complex craniomaxillofacial trauma and reconstruction^[7]. The use of preoperative 3-dimensional (3D) planning, in particular, has the potential to drastically reduce operating room (OR) time and OR costs. 3D model fabrication with preoperative plate bending is a cost- and time-effective option to provide predictable reconstructive solutions with an associated decrease in operative time and cost^[8].

CASE 1:

A 37-year-old male patient presented to our department with a history of road traffic accident. He complained of pain in the right lower third of the face with difficulty in opening the mouth. Step deformity was palpable in the right angle of the mandible region and between 32 and 33 teeth along with anterior open bite and right posterior cross bite. After thorough clinical and radiographic examination, a diagnosis of left parasymphysis and displaced right mandibular angle fracture was made. An open reduction and internal fixation using miniplates was planned.

Using high resolution CT scan of the patient DICOM images were extracted, this was then converted into .stl format and 3d printed model of the fractured mandible and the maxillary dentoalveolar segment was printed (Projet 3500 ;3 D Systems) using PLA material(fig1,2). Virtually, the direction of displacement of the fractured fragments was analyzed.

Mock surgery was performed on 3d printed mandible in which model was cut along the fracture lines and separated segments were reduced in correct anatomical position by using the occlusal plane as the guide. The fractured segments were connected with wax in the model to stabilize them.

A 2mm 4 holed miniplate was then adapted along the external oblique ridge on the model. A 2mm 3D plate was bent and adapted to the contours of the fracture in the parasymphysis region(fig3,4).




Figure 1:Parasymphysis fracture in 3D printed model

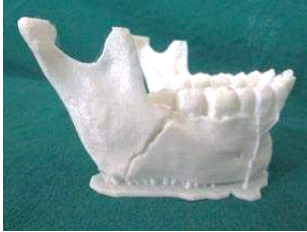

Figure 2:Angle fracture in 3D printed model

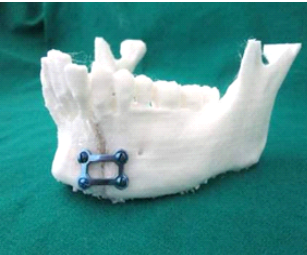
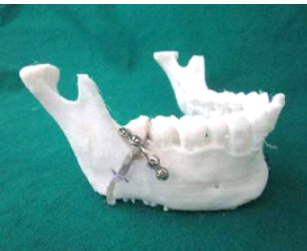

Figure 3:3D plate fixation in parasymphysis fracture



Intraoperatively,satisfactoryanatomical reduction was achieved, and the fractured segments were fixed using these pre-bent miniplates along the Champy's lines of osteosynthesis(fig.5,6). A follow up after 3 showed anatomical reduction with no malocclusion, infection, or segmental mobility with bilateral class 1 molar relation.

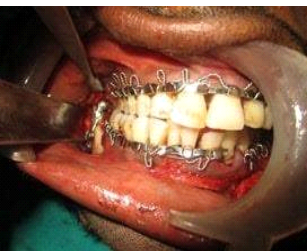


Figure 5: 3D plate fixation in angle fracture

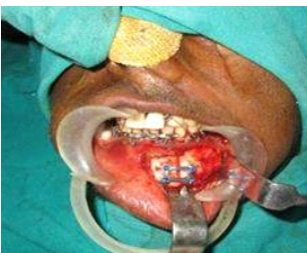

Figure 6: Prebent 3D plate fixation done in parasymphysis fracture

CASE 2:

A 34-year-old patient reported at our department with a history of road traffic accident. He complained of pain in the right side of the lower third of the face and difficulty in opening his mouth. On examination a diffuse extra-oral swelling was present on right lower third of the face with an anterior open bite and right posterior cross bite. After radiographic examination, diagnosis of right mandibular body and left displaced sub condylar fracture was reached. Surgery of choice decided was open reduction and internal fixation of the body and condylar fracture.

Preoperative CT scan of the patient was imported in MIMICS software and virtual surgical planning was performed in which fractured segments were virtually reduced (fig:7,8,9,10).

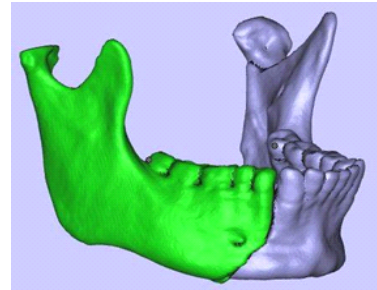


Figure 7:Virtual Body fracture

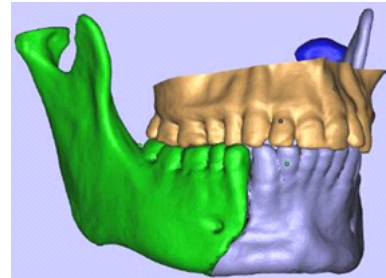


Figure 8:Virtual body fracture reduction

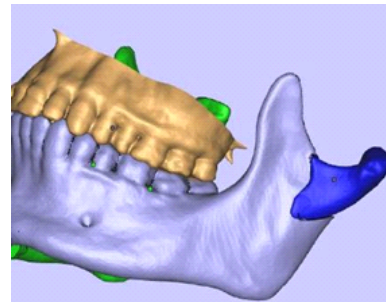


Figure 9: Left mandibular condyle fracture

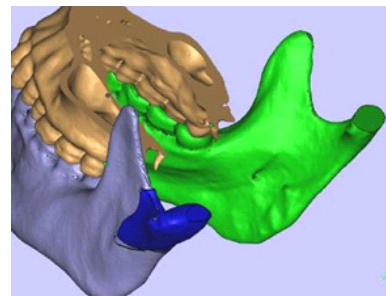


Figure 10:Virtual condylar fracture reduction

Further 3d printed model of maxilla and mandible were printed using PLA material. Fracture lines were identified, and our earlier diagnosis was confirmed after three-dimensional analysis of the model. Model was separated at fracture lines and reduced in correct

anatomical position using occlusion as guide. After reducing the condylar segment, a rhomboid shaped plate was bent and adapted to fix the condylar segments(fig:11). Two 4-holed miniplates were also adapted to the fractured area in the body region(fig:12). These pre-bent plates were then sterilized in an autoclave.

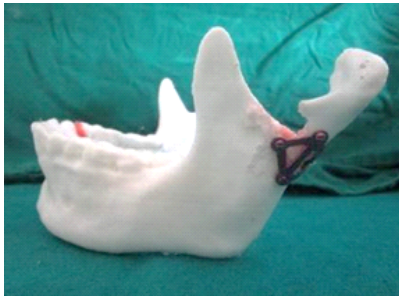

Figure 11: 3d plate fixation in condyle fracture on 3D printed model

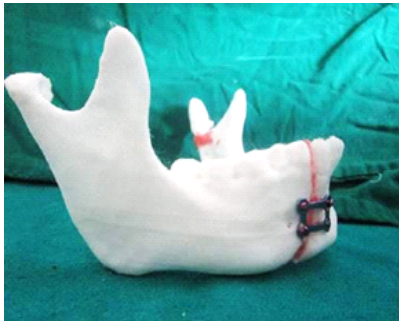

Figure 12: 3D plate fixation in body fracture on 3D printed model.

Intraoperatively, it was easier to achieve an anatomical reduction as the fracture displacement was well analyzed virtually and on the model. After reduction, the pre-bent plates were used for fixation of the segments(fig:13,14). These plates not only adapted perfectly but also served as a guide for the reduction of the condylar fracture which is usually difficult to visualize easily. It was assumed that if the plate adapted perfectly the reduction was accurate. These preadapted plates were used to stabilize fractured segments intraoperatively.

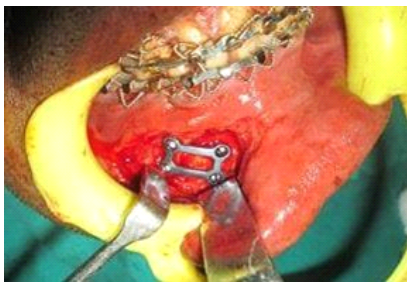


Figure 13: Pre-adapted 3D plate fixation

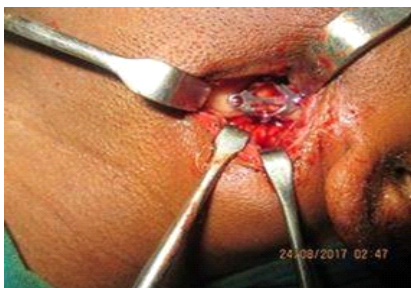

Figure 14: Pre-adapted 3D plate fixation

A follow-up after 3 months showed anatomical reduction with no

malocclusion, infection or segmental mobility with bilateral class 1 molar occlusion.

CASE 3

A 10-year-old patient with a history of assault reported to our department with the chief complaint of pain in the lower front region of his jaw. Examination revealed left anterior open bite and premature contact on the right with segmental mobility between 42 and 43 regions. Provisional diagnosis of right mandibular fracture was made, and as it was a pediatric fracture, closed reduction using a cap splint was decided as treatment plan.

DICOM data in the form of patients CT scan was exported in MIMICS virtual surgical planning software. Virtually the mandible was cut at fracture line and separated segments were realigned by using occlusion as the guide. Once confirmed, that segments were in correct position, a cap splint was designed over the anterior teeth of the mandible digitally(fig:15). The splint was designed with a clearance of 0.1 mm and was extended from deciduous first molar bilaterally.

The fit of the splint was perfect and did not need any intraoperative corrections. After one-month the splint was removed, and the occlusion was found to be satisfactory.

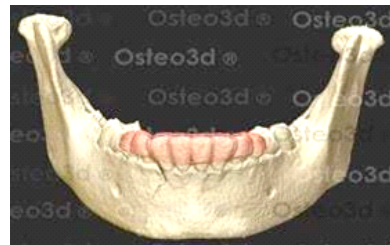

Figure 15: virtually designed cap splint

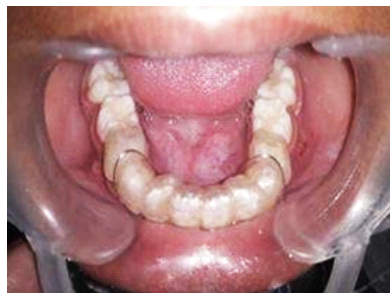


Figure 16: 3D printed cap splint

The thickness of the splint was 3 mm so that

DISCUSSION

it would be rigid enough to fix the mandible. Finally, the splint was 3D printed in a translucent photopolymer resin (ISO 13485 certified) using an SLA printer(fig:10).

Under general anesthesia this prefabricated splint was fixed to the mandibular anterior teeth using circummandibular wiring, ensuring that the occlusion was centric and stable (fig:16).

Conventionally reduction in mandibular parasymphysis fracture is performed using occlusion and lower border of mandible as a guide, but this doesn't enable us to analyse lingual reduction. With the help of a CT scan and virtual planning, it is possible to visualize the lingual cortex reduction. The STL images that were generated from DICOM data enabled us to visualise the displacement of each of the fractured segment. The printed models further enhance this view. The plates are adapted based on this accurate reduction. Three-dimensional visualisation of the fracture segment allows reduction keeping the lingual displacement in mind. This accurate reduction was transferred intra operatively by using pre-operative miniplates

by placing plates at the position of passive fit. Pre-bending of a 3D plate for a parasymphysis fracture made it easy for the surgeon to not only get an accurate reduction but also to get easier anatomical reduction and better surgical fixation significantly reducing the surgical time. Angle fractures are difficult to fix intraorally. Holding the fracture in the reduced position while bending and adapting the plates along the external oblique ridge can be very challenging especially for a novice surgeon. This process has been simplified by using the patient's 3D printed mandible and pre bending the plates. Brett J King^[9] in his study obtained similar results in which he used 3D printing technique for treatment of mandibular fracture cases.

In the management of mandibular condylar fractures 3D printing plays a significant role. The virtual images of the condylar fractures help us to understand the exact position of the condylar stump in relation to the ramus of the mandible. This gives us and insight into what type of incision can be placed whether retro mandibular, submandibular or pre-auricular to get an adequate exposure of the fracture site. The pre-estimated position of the condylar stump allows us to easily identify its position and relocate it on to the ramus to get a good anatomical reduction. Preadaptation of a 3D plate extending from the lateral surface of the condyle to the posterior border of the condyle is very advantageous. The pre-adapted plate not only fits passively but also guides the condyle into its position as determined on the model and allows a perfect fixation.

In the management of pediatric mandibular parasymphysis fracture using 3D printed cap splint we were able to get an accurate reduction since the mandible can be visualized 3 dimensionally. Use of virtual planning reduces chances of human error which can occur due to involvement of extensive laboratory procedure like impression making, fabrication of cast, sectioning and fracture reduction on cast followed by cap splint fabrication. This cap splint fabricated using 3D printing was aesthetically acceptable when compared to the conventional cap splint fabricated using acrylic because the dental morphology was incorporated. Since we used a SLA technology for the print using a resin the splint was transparent which improved the esthetics. The duration of surgery was significantly reduced and exposure to general anaesthesia was minimal. This is because the customized splint did not need any adjustments intraoperatively. Jung-woo Lee^[10] used virtual surgical planning and 3D printed splint for management of paediatric mandibular fracture and his study results were similar to our results.

CONCLUSION

In the management of mandibular trauma patients virtual surgical planning enables the operator to visualize the fracture site three-dimensionally which in turn allows the operator to make a detailed analysis of the fracture. With the information the operator can formulate the most suitable treatment plan for the patient. Mock surgery performed on the 3d printed model helps novice surgeons to perform reconstruction with high level of accuracy. Intra operative transfer of pre-operative surgical planning of mandibular reconstruction can be achieved by using pre-bent mini plates. Use of pre-bent plates also reduces duration of surgery and maintains physical properties of the plates intact as it does not require multiple bending intra-operatively. Computer assisted additive manufacturing in management of paediatric mandibular fracture patient was found to be beneficial as it reduced the patient discomfort by eliminating painful impression procedures. Also, reduces human errors of fabrication of splint and significantly reducing surgical time and produces a more aesthetically pleasing splint.

REFERENCES

- [1] Azevedo AB, Trent RB, Ellis A. Population-based analysis of 10,766 hospitalizations for mandibular fractures in California, 1991 to 1993. *J Trauma*. 1998;45(6):1084-7.
- [2] Wolfswinkel E, Weathers W, Wirthlin J, Monson L. Management of Pediatric Mandible Fractures. *Otolaryngologic Clinics of North America*. 2013;46(5):791-806.
- [3]. BuiTG, BellRB, DierksEJ. Technological advances in the treatment of facial trauma. *Atlas Oral Maxillofac Surg Clin North Am*. 2 0 1 2 ; 2 0 (1) : 8 1 - 9 4 . doi:10.1016/j.cxom.2011.12.006 [4]. Azarmehri, StokbroK, BellRB, Thygesen T. Surgical

Navigation: A Systematic Review of Indications, Treatments, and Outcomes in Oral and Maxillofacial Surgery. *J Oral Maxillofac Surg*. 2 0 1 7 ; 7 5 (9) : 1 9 8 7 - 2 0 0 5 . doi:10.1016/j.joms.2017.01.004

- [5]. Sukegawa, S., Kanno, T. and Furuki, Y., 2018. Application of computer-assisted navigation systems in oral and maxillofacial surgery. *Japanese Dental Science Review*, 54(3), pp.139-149.
- [6] BellRB. Computer planning and intraoperative navigation in cranio-maxillofacial surgery. *Oral Maxillofac Surg Clin North Am*. 2 0 1 0 ; 2 2 (1) : 1 3 5 - 1 5 6 . doi:10.1016/j.coms.2009.10.010
- [7] Avraham T, Franco P, Brecht LE, et al: Functional outcomes of virtually planned free fibula flap reconstruction of the mandible. *Plast Reconstr Surg*. 2014 Oct;134(4):628e-34e
- [8] Seruya M, Fisher M, Rodriguez ED: Computer-assisted versus conventional free fibula flap technique for craniofacial reconstruction: An outcomes comparison. 2013 Nov;132(5):1219-28
- [9]. King B, Peter Park E, Christensen B, Danrad R. On-Site 3-Dimensional Printing and Preoperative Adaptation Decrease Operative Time for Mandibular Fracture Repair. *Journal of Oral and Maxillofacial Surgery*. 2018;76(9):1950.e1 - 1950.e8.
- [10]. Lee, Jung-Woo et al. "Minimal Invasive Treatment Using Patient-Specific Template For Mandibular Fractures In Children: "Wing-Splint" By CAD/CAM Technology". *British Journal of Oral and Maxillofacial Surgery* 54.10 (2016): 1140-1141