

ENT

KEYWORDS:

Mucormycosis, Maxillary Sinus, Amphotericin, Endoscopic Sinus Surgery, Pterygo Palatine Fossae, Infra Temporal Fossae, Maxillectomy.

MAXILLARY SINUS INVOLVEMENT IN MUCORMYCOSIS-OUR EXPERIENCE



Volume - 7, Issue - 1, January - 2022

ISSN (O): 2618-0774 | ISSN (P): 2618-0766

| | |
|------------------------------|--|
| Dr.k.Ramesh Babu | MS(ENT),, Associated Professor, Govt. Thiruvarur Medical College Thiruvarur. |
| Dr. Gerald Parisutham | MS.,DLO. Assistant Professor, Department Of Ent, Thanjavur Mdical College Thanjavur. |
| Dr.Dharma Raja | MS(ENT),, Assistant Professor Department Of Ent, Thanjavur Mdical College Thanjavur. |
| Dr.b.Ganesh Kumar* | M.S., D.L.O, Associate Professor, Department Of Ent, Thanjavur Mdical College Thanjavur*Corresponding Author |

INTERNATIONAL JOURNAL OF PURE MEDICAL RESEARCH



ABSTRACT

INTRODUCTION: Mucormycosis is a lethal disease in this Covid-19 Pandemic. It has more predilection to affect the patients in Immuno compromised state like Diabetes, On Prolonged Steroid therapy, and AIDS. Maxillary sinus involvement is the Most common in Mucormycosis compared to the other sinuses. **OBJECTIVE** Study about the Maxillary sinus and it's various walls Involvement, and to Know the extension into adjacent regions, to know about the various types of surgical treatments used for Mucormycosis clearance. **STUDY DESIGN:** Retrospective Study, Analytical Study. **MATERIALS AND METHODS:** Study was conducted in Govt Thanjavur Medical College, ENT Department from May 2021 - July 2021. Total Number of patients are 78. All cases are subjected to Clinical Evaluation, DNE, Radiological Investigation and taken for Endoscopic Sinus Surgery and other types surgery followed by Post Operative Systemic Amphotericin. All are discharged after 1week and Followed regularly every week with Endo Cleaning. **RESULTS:** In our Study Males are affected more in Number. Commonest Age group involved are 21-40 years. Medial wall of Maxillary sinus are commonly involved in 30 cases, followed by Palatal involvement (16 cases) and Pterygo Palatine Fossae and Infra Temporal Fossae involvement (14 cases). Pre Maxillary region and Anterolateral wall involvement in 12 cases, followed by Floor of Orbit involvement in 6 cases. Endoscopic Sinus Surgery commonly performed for 24 cases, followed by Endoscopic Medial Maxillectomy (16 cases), and Pterigo Maxillary Fossae exposure and Infra Temporal Fossae Exposure in 14 cases. Strong Positive Association present between Diabetes and Post Covid Status. **DISCUSSION:** Maxillary sinus and it's various wall involvement in Mucormycosis is common than other sinus. Early diagnosis with clinical findings such as Nasal Obstruction, Purulent Nasal Discharge, Numbness over Infra Orbital region, Ptosis, Loosening of tooth, Trismus due to Medial Pterygoid Muscle Involvement. CT PNS plays major role in defining the Bony Landmark of Maxillary Sinus. MRI plays Vital role to identify the extent of Devitalised Tissue by that the Type of Surgical Procedure can be decided. Operated Tissue Material sent for both Histopathological Examination and Fungal Culture, by that Post Operative Amphotericin started. Adequate Glycemic Control is very important by that Disease Extension and it's related complication and Mortality reduced. Regular Weekly Post Operative Follow up with Endo Cleaning is very effective in reducing Recurrence. **CONCLUSION;** Among all the Sinuses Maxillary Sinus is commonly involved. Early diagnosis with Supportive Radiological evidence is important for Early Surgical Debridement. Adequate Antifungal

therapy is mandatory. Post operative Endo Cleaning with Step down therapy with Oral Antifungal agents is very important. Control of Predisposing factors plays vital role.

INTRODUCTION:

Mucormycosis also known as Zygomycosis or Phycomycosis was First described by Paultauf in 1885. It was characterised by Opportunistic, Rapid, Fatal infection. Angioinvasion is the main mode of spread and more towards Arteries than Veins and grows along Internal Elastic Lamina causing Thrombosis and Infarction [1].

It belongs to Zygomycetes, including Mucor, Rhizopus, Abisidia, and Rhizomucor and it was Thermo-Tolerent. It was present in Natural Environment like Soil, Animal Faeces and Decaying Plant Materials, and infect the Immunocompromised and Uncontrolled Diabetes patients. It was the Most Common Invasive Fungal Lesion after Aspergillosis and Candidiasis [2].

Most of the time this fungal infection originate from Paranasal Sinuses especially Maxillary Sinus. Once the Non Septate ,Right Angled Branching Hyphae entering into blood vessels it will reach vital organs like Lungs, Brain and Orbit and causes Thrombosis followed by Tissue Necrosis.

Chronic Diabetes patients are vulnerable for local Tissue Ischemia and Infecions , because of Microangiopathy and Atherosclerosis. So in Uncontrolled Diabetes with Mucormycosis of Maxillary sinus involved patients are more Vulnerable for Thrombosis of Internal Maxillary and Descending Palatine Artery results in Necrosis of Maxilla and Palate [3].

Maxilla is one of the Primary bones of the face forms Upper Jaw. It takes part in the formation of Palate, Nose and Orbit. Alveolar Process of Maxilla having the teeth and is very important for Mastication and Speech. Necrosis of Maxillae is very rare because of its high blood supply [4].

Maxillary bone necrosis occurs in Bacterial infections like Osteomyelitis, Viral infections like Herpes Zoster, Fungal infections like MucorMycosis, Trauma and after Radiation for the treatment of Sinonasal Malignancy [5].

Increased incidence of Mucormycosis in India is mainly due to increased Population , Uncontrolled Diabetes Mellitus, and Environmental factors like Humid Climate and High temperature which favours for increased surveillance of Mucormycosis. Reviewing the Literature of past 5 decades (1960-2012) showed the Prevalence Rate for Mucormycosis was 0.14 cases per 1000 population [6].

Symptoms of Mucormycosis are Nasal Stuffiness, Infra Orbital Numbness, Palatal Erosion, Trismus due to Medial Pterygoid Muscle Involvement. Infected Tissues appears Normal at the Earliest Phase, followed by Intermediate Erythematous Phase and Finally the Classical Black coloured Eschar due to Thrombosis of involved Arteries. Palatal Involvement is direct extension of the Disease from Maxillary Sinus and also involving the Spheno Palatine and Greater Palatine Artery involvement. Pain followed by Swelling of Palatal region followed by separation of Mucosa from palate and Ultimately results in Palatal Perforation [7].

Mucormycosis cases spread into the Pterygo Palatine Fossae and from there to Infra Temporal Fossae ,through the erosion of Posterior wall of Maxilla. Symptoms are Difficulty in mouth opening and Unilateral facial swelling in Infra Temporal region. Through the Erosion of Orbital Floor , Intra and Extra Ocular muscles are involved resulting in Unilateral Peri Orbital pain, Ophthalmoplegia, Restricted Eye Movements, Head ache and Acute Vision loss [8].

Pre Maxillary region Swelling is common after the Erosion of Antero Lateral wall of Maxillary Sinus. All cases are Evaluated with CT and MRI Paranasal Sinuses and after getting various opinions like Ophthalmology, Dental Surgery, Neuro Surgery ,and Diabetology. Patient was subjected to Various types of Surgical Debridement like Endoscopic Sinus Surgery, Denker's Procedure, and Maxillectomy.

Systemic Amphotericin Injection Followed by Solvage therapy with Tablet Posaconazole is very important to reduce recurrence. Weekly Postoperative Endo cleaning is mandatory.

OBJECTIVES:

Study about

1. The Maxillary sinus and it's various walls Involvement,
2. To Know the extension into adjacent regions,
3. To know about the various types of Surgical Treatments used in Mucormycosis Management.

STUDY DESIGN:

Retrospective Study, Analytical Study.

MATERIALS AND METHODS:

Study was conducted in Government Thanjavur Medical College, in Department of ENT and Head and Neck Surgery from May 2021 - July 2021. Total Number of patients are 78. Patients with limited Maxillary Sinus disease and extended trough it's walls alone taken for study. Other Sinus involvement cases are Excluded.

All cases are Evaluated by the Clinical Features like Nasal Obstruction, Swelling in Pre Maxillary region, Infra Orbital Numbness, Trismus, Infra Temporal Fossae Swelling. Diagnostic Nasal Endoscopy was done for all cases, which reveals the Block coloured Gangrenous ESCHAR diagnostic of Mucormycosis.

Radiological Investigation consists of CT PNS gives details about the Bony Boundaries of Maxillary Sinus clearly. MRI is very important to know about the Viable status of Soft tissues adjacent to Maxillary sinus especially in Pterygo Palatine Fossae.

All patients underwent Early and Forcible Endoscopic Sinus Surgery and other approaches depending upon the Extension. Tissue Specimen sent for HPE and Fungal Culture and Started with Inj. Amphotericin. All are discharged after 1 to 2 weeks and followed regularly Every Week for Endo Cleaning. All are Counselling regarding Importance of Management of their Individual Predisposing factors for the development of Mucormycosis.

RESULTS:

TABLE-1:SEX DISTRIBUTION

| SEX | NUMBERS |
|------|---------|
| MALE | 46 |

| FEMALE | 32 |
|--------|----|
|--------|----|

PIE CHART-1:

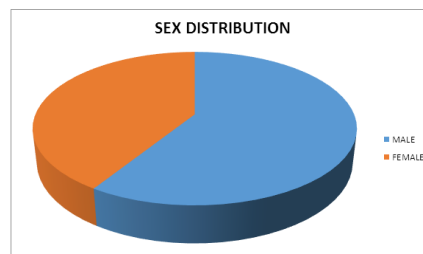


TABLE-2:AGE DISTRIBUTION

| AGE GROUP | NUMBER OF PATIENTS |
|----------------|--------------------|
| 0-20 YEARS | 2 |
| 21-40 YEARS | 36 |
| 41-60 YEARS | 26 |
| ABOVE 60 YEARS | 14 |

PIE CHART-2:

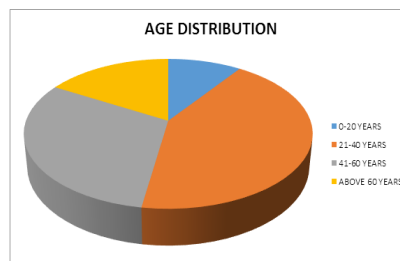


TABLE-3:PREDISPOSING FACTORS.

| PREDISPOSING FACTORS | PRESENT | ABSENT |
|-------------------------|---------|--------|
| DIABETES MELLITUS | 60 | 18 |
| POST COVID-19 | 66 | 12 |
| STEROID TREATMENT. | 46 | 32 |
| OXYGEN TREATMENT | 41 | 37 |
| IMMUNOSUPPRESSION DRUGS | 3 | 75 |

BAR CHART-1.PREDISPOSING FACTORS:

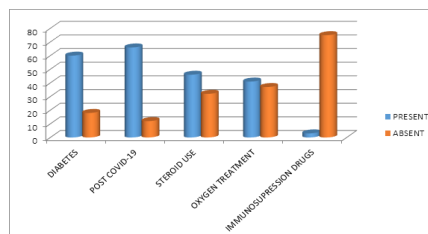


TABLE-4:MAXILLARY SINUS WALLS INVOLVEMENT.

| MAXILLARY SINUS WALLS | NUMBER OF PATIENTS |
|-------------------------------------|--------------------|
| ANTEROLATERAL& PRE MAXILLARY REGION | 12 |
| POSTERIOR WALL & PPF & ITF | 14 |
| MEDIAL WALL | 30 |
| FLOOR OF ORBIT | 6 |
| PALATAL INVOLVEMENT | 16 |

PIE CHART-3:MAXILLARY SINUS WALL INVOLVEMENT

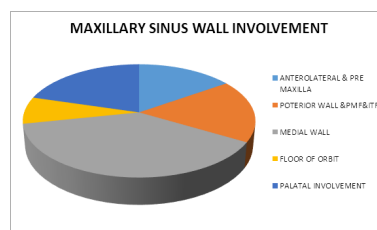
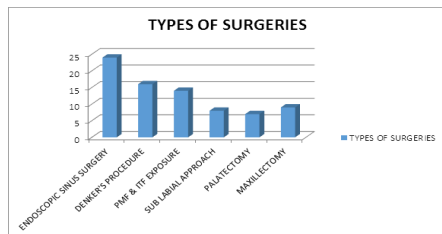


TABLE-5: TYPES OF SURGICAL PROCEDURES:

| TYPES OF SURGERY | NUMBER OF PATIENTS |
|--------------------------|--------------------|
| ENDOSCOPIC SINUS SURGERY | 24 |
| DENKER'S PROCEDURE | 16 |
| PPF & ITF EXPOSURE | 14 |
| SUB LABIAL APPROACH | 8 |
| PALATECTOMY | 7 |
| MAXILLECTOMY | 9 |

BAR CHART-2. TYPES OF SURGICAL PROCEDURES.



RESULTS:

In our Study Males (46cases) are 59% Predominantly affected than Females (32 cases) which contributes 41%. It was revealed in Table-1 and Pie Chart-1.

Table-2 and Pie Chart-2 Shows the pattern of Age group representation. 46% of patients (36 cases) belongs to 21-40 years, Followed by 33.5% of 41-60 years of age group (26 cases) and 18% of Above 60 years (14cases) age group. Less than 20 years (2 cases) are affected very minimally 2.5%.

Table-3 and Bar Chart-1 displays the various Predisposing Factors related to the development of Mucormycosis. Strong Positive Correlation present between Diabetes Mellitus, Steroid usage, Post Covid Status, Oxygen treatment and the development of Mucormycosis in our study.

Table-4 and Pie-Chart-3 reveals the number of cases related to each wall of Maxillary Sinus and it's adjacent region. Medial wall of Maxillary Sinus involved (30 cases) in 38% of cases. The Next major group 21% belongs to Floor of Maxillary Sinus (Palate and Alveolar ridge involvement) are 16 cases, Followed by Posterior wall and extension into Pterygo Palatine Fossae and Infra Temporal Fossae (14 cases and 18%), Antero lateral wall and Pre Maxillary region in 15% (12 cases) and in 8% of (6 cases) patients Floor of Orbit is (Roof of Maxillary Sinus) involved.

Table-5 and Bar Chart-2 shows the various types of Surgeries performed for disease clearance in our study. Endoscopic Sinus Surgery was done for 24 cases (31%), followed by Endoscopic Medial Maxillectomy (Denker's Procedure) 16 cases (21%), Exposure of Pterygo Palatine Fossae and Infra Temporal Fossae in 14 cases (18%), Various types of Maxillectomy in 9 cases (12%), Sub Labial approach for Pre Maxillary Region in 8 cases (9.5%) and Palatectomy in 7 cases (8.5%).

DISCUSSION:

The Nomenclature of Mucormycosis is based on Anatomic site localization rather than by Mycologic Classification. For the Head and Neck region it was classified into, Nasal, Rhino-Orbital, Rhino-Orbito-Cerebral types. Other accepted forms are Pulmonary, Cutaneous, Disseminated, Gastro Intestinal and Miscellaneous.

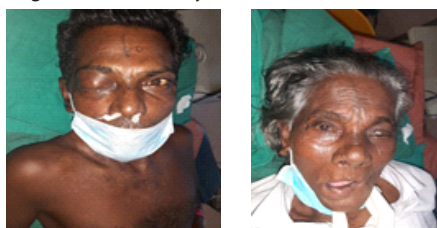Rhino-Orbital-Cerebral-Mucormycosis (ROCM) occurs commonly in Post COVID_19 and Poorly controlled Diabetes Mellitus especially with Diabetic Keto Acidosis, Iron Overload, patients on Glucocorticosteroid and Neutropenia related Haematologic malignancies.

The Fungi produces its pathologic lesions by its Angio invasion,

followed by Thrombo Embolism and Tissue necrosis. This fungi have a Predisiction for Internal Elastic Lamina of arteries. Later it will separate the Internal Elastic lamina from Media and causes Extensive Mucosal Damage resulting in Thrombous Formation followed by Ischemia of Surrounding tissues.

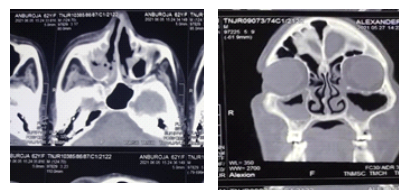
Infarcted tissues favours the Mucor growth by creating suitable Environment. Poor Blood supply prevents the Effects of Systemic Medical Therapy to control it's growth. The Nose and Para Nasal Sinuses are involved through the Blood vessels. Orbit was involved secondarily via Communicating Foramens or Venous channels. Cranium is involved through the Cribriform plate , through Orbital Apex and Roof of Ethmoids (Fovea Ethmoidalis)[9].

Song G et al study reveals that 99 cases of Post Covid -19 Fungal infections, 5% cases are due to Aspergillosis and 7% of cases are due to Mucormycosis. Their study showed that Impaired T Cell immunity along with the Immunocompromised state is very important for the Pathogenesis of Mucormycosis[10].



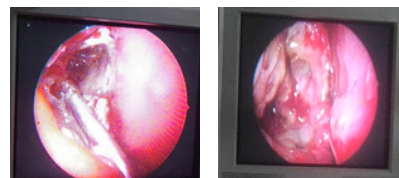
Waiting for Culture Report for Initiation of Treatment is not a mandatory one. Clear clinical picture of Mucor and Positive Nasal Smear report is enough to start Antifungal treatment. Diagnosis is classically depends upon Clinical Symptoms, Endoscopic Findings and Radiological Imaging such as CT and MRI to assess the Extent of tissue Involvement. Early Diagnosis and Proper treatment will lead to good results with reduced chances of recurrence [11].

CT -PNS shows the Bony Landmark clearly and MRI is Inconclusive in early phase of Disease, later on it reveals the soft tissue status of involved regions by that the Surgical plan was modified. MRI shows Hypo to Iso Intense lesions on T1 images, and If the T2 image shows Hypo intense lesions it Indicates Fungal elements ,which concentrate Iron and Manganese. Post Contrast Images shows Intense Enhancement of involved sinuses. There may be Heterogeneous Opacity or Complete Hypo intense lesions due to Tissue Necrosis produced by Mucormycosis [12].



Surgical debridement should be done in Early phase itself and it should be Aggressive manner. The Criteria to stop the procedure was If there is Fresh Bleeding from the tissues and Felling of pain sensation in case of Local Anaesthesia.

Endoscopic Sinus Surgery with Debridement of involved tissues is the mainstay of treatment. If there is difficulty to reach more Posterolateral wall of Maxillary sinus then Sub Labial Approach will be better for that situation. For Pre- Maxillary region involved cases also Sub Labial approach useful. Many cases are presented with Pre Maxillary swelling and it was drained by this approach.



In case of Pterygo Palatine Fossae (PPF) and Infra Temporal Fossae (ITF) involved cases, Endoscopic Medial Maxillectomy (Denker's Procedure) or Extended Medial Maxillectomy can be done. Naso Lacrimal System Should be dealt properly to avoid Post Operative Epiphora in this type of procedures.

Mucormycosis involved in PPF and ITF will be presented as Necrosis of Fat which was the prominent content of that region and Mucopurulent discharge. Most of the time the Internal Maxillary Artery found as a Cord like structure due to its Thrombosis. utmost care should be taken for Internal Maxillary Artery haemostasis, because Post Operative Bleeding from the Cut End of the vessel is a troublesome.

Ophthalmic Surgeon help is Mandatory if the disease extended Intra Ocularly. Extra Conal involved cases may be treated by Endoscopic Orbital Decompression by incising the Medial wall of the Orbit. Other Extensive involved cases requires Orbital Exenteration or Enucleation or Evisceration.

Palatal lesions depending upon its extent treated by various procedures like Eschar removal alone, Eschar removal along with Curettage of Palate, Palatotomy and later on with Flap cover.

Patients presenting with Loosening of teeth shows that Alveolar Process of Maxilla is involved. This type of cases need Resection of Alveolar process alone and if there is adjacent Palate also involved, treated by Sub Total Maxillectomy. Extensive and in Recurrent Lesions Maxillectomy is the treatment of choice. Dental Surgeons help is very important for Post Operative Obturator and Further follow up of Maxillectomy cases.

Specimen of operated tissues of all cases should be sent for Histopathological Examination, and Fungal Culture, which was very essential for both treatment part and also for Documentary Evidence. This should be Followed by Systemic Amphotericin. Good Glycemic Control is very important in Controlling the Disease Spread and also reducing the Recurrence Rate.

After Discharge all patients are advised for regular Weekly Follow up for Endo Cleaning and if needed Revision Debridement. All Patients are maintained with Salvage therapy with Tab. Posaconazole 300mg BID on first day followed by 300 OD for 4-6 weeks.

CONCLUSION:

In Our Study Males and 21-40 years of age group are commonly affected. Majority of cases are associated with Diabetes, Post Covid Status, and Oxygen treatment. Medial wall of Maxillary sinus was affected more in number followed by Posterior wall and Floor. Endoscopic Sinus Surgery and Medial Maxillectomy was done in more cases, followed by Pterygo Palatine Fossae and Infra Temporal Fossae Exposure. Maxillectomy and Palatotomy done for Extensive Palatal involved and Recurrent cases.

REFERENCES:

1. Ameen M, Arenas R, Martinez-Luna E, Reyes M, Zacarias R. The Emergence of Mucormycosis as a Opportunistic Fungal Infection. *Inter J Dermatol* 2007; 46: 380-384.
2. Metzgen D, Bohm H, Zimmermann M, Reuther T, Kubler AC, Muller Richter UD. Mucormycosis of Head and Neck, *J Craniomaxillofac Surg* 2012; 40: e321-7.
3. Jones AC, Bentsen TY, Fredman PD. Mucormycosis of Oral cavity, *Oral Surg Oral Med Oral Pathol* 1993; 75: 455-60.
4. A. Urs, H.Singh, S.Mohanty and P.Sharma. "Fungal Osteomyelitis of Maxillofacial Bones: Rare Presentation", *Journal of Oral and Maxillo Facial Pathology*, Vol.20, no.3, p.546. 2016.
5. J.A. Kumar, P.Babu, K.Prabu, and P.Kumar, "Mucormycosis in Maxilla: Rehabilitation of Facial Defects using Interim Removable Prosthesis: a case report. *Journal of Pharmacy and Bioallied Sciences*, vol 5, no. 2, p. 5163. 2013.
6. A. Chakrabarti and R.Singh, "Mucormycosis in India: unique features" *Mycoses*, vol.57, pp85-90, 2014.
7. Tugsel Z, Sezer B, Akalin T. Facial Swelling and Palatal Ulceration in a Diabetic Patient. *Oral Surg, Oral Med, Oral Pathol, Oral Radio, Endod*, 2004; 98: 630-636.
8. Cheema SA, Amin F. Five cases of Rhino Orbito Cerebral Mucormycosis. *Br J Oral Maxillofacial Surgery* 2006; 45: 161-162.
9. Petrikos G, Skiada A, Sambatakou H et al. Mucormycosis: Ten year Experience in Tertiary care centre in Greece. *Eur J Clin Microbiol Infect Dis* 2003; 22: 753-756.

10. Song G, Liang G, Liu W. Fungal Co infections associated with global Pandemic: a clinical and diagnostic perspective from china. *Mycopathologia*, 2020; 185: 599-26.

11. P.G. Duetsch, J. Whittaker, S. Prasad. Invasive and Non Invasive Fungal Rhino Sinusitis- a Review and Update of Evidence. *Medicina* 55 (2019) 1-14.
12. M.R. Terk, D.J. Underwood, C.S. Zee, P.M. Colletti. MR Imaging in Rhinocerebral and Intracranial Mucormycosis with CT and Pathologic Correlation. *Magn Reson Imaging*, 10 (1992): pp 81-87.