

## Cardiology

**KEYWORDS:** Bawaseer, fig & Prunes, Aabzan (Illaj-Bit-Tadbeer)

## MULTIVALVULAR INVOLVEMENT IN SCHEIE SYNDROME



Volume - 5, Issue - 1, January - 2020

ISSN (O): 2618-0774 | ISSN (P): 2618-0766

<b>B. Madhava Rao</b>	Department of General Medicine, Maharaja Institute of Medical Sciences, Nellimarla 535217, Andhra Pradesh, South India
<b>L.Srinivasa Rao</b>	Department of General Medicine, Maharaja Institute of Medical Sciences, Nellimarla 535217, Andhra Pradesh, South India
<b>Satya kumar k *</b>	Department of General Medicine, Maharaja Institute of Medical Sciences, Nellimarla 535217, Andhra Pradesh, South India *Corresponding Author satkot83@gmail.com
<b>M.Rajasekhar Reddy</b>	Department of General Medicine, Maharaja Institute of Medical Sciences, Nellimarla 535217, Andhra Pradesh, South India
<b>D.Harshavardan</b>	Department of General Medicine, Maharaja Institute of Medical Sciences, Nellimarla 535217, Andhra Pradesh, South India
<b>B.Gowtham</b>	Department of General Medicine, Maharaja Institute of Medical Sciences, Nellimarla 535217, Andhra Pradesh, South India

### INTERNATIONAL JOURNAL OF PURE MEDICAL RESEARCH



The mucopolysaccharidoses constitute a group of heritable disorders characterised by abnormal accumulation of mucopolysaccharide material in various tissues. They are diagnosed by a combination of clinical, radiological and biochemical features. The mucopolysaccharidoses (MPS) are genetically classified into seven types by McKusick V.A.1 A common feature of several of these disorders is cardiac involvement. We report a family of Scheie syndrome (MPS I-S) with multivalvular involvement. To the best of our knowledge this is being reported for the first time in India.

#### Material and Methods

Two sisters RP and RK were born fullterm and normally to distantly related Parents. RP and RK had slightly delayed milestones of development. From the age of 4 years parents noticed coarse facies (Fig. 1), joint stiffness, widening of wrists, clawing of hands and progressive kyphoscoliosis. She was suffering from progressive dyspnoea on exertion for the past six months and suffered one episode of effort syncope at the age of 9 years. Physical examination revealed head circumference of 54 cm, normal intelligence, peripheral clouding of cornea with clear centre, thick lips, enlarged tongue and restricted mobility of small joints of hands and feet, wrists, elbows, knees with kyphoscoliosis. Firm liver was palpable 3 cm below the right coastal margin. Cardiovascular system revealed pulse 80 per mt, regular, low volume, no brachiofemoral delay. B.P.100/90 mm, Hg. J.V.P. 5 cm from sternal angle with prominent 'a' and 'v' waves. Apex was not localised. First sound was muffled second sound was normally split with soft A2 and loud P2. There was no opening snap. A grade 3/6 ejection systolic murmur was heard over the aortic area with conduction to the carotids and grade 2/6 pansystolic murmur at the apex with conduction to the left axilla. A rough, rumbling middiastolic murmur with presystolic accentuation was also heard at the apex. Respiratory and neurologic systems were normal.

RK had normal milestones of development and was asymptomatic except for milder degree of stiffness of various joints. She had relatively less coarse facies (Fig. 1), height of 112 cms, head circumference of 51 cms, normal intelligence, peripheral

#### Investigations

Routine blood and urinalysis were essentially normal. E.C.G. of C.G. showed sinus rhythm, heart rate of 75 per mt, left atrial enlargement, left axis deviation, left ventricular hypertrophy, normal ST-T and no conduction abnormalities. Skiagram of chest showed cardiothoracic ratio of 60%, L.V. enlargement, left atrial enlargement and mild pulmonary venous hypertension. X rays of hands showed (Fig. 2) classical broad metacarpals 2,3 with widening of shafts, fingers were held in a 'claw' position with cystic changes in the phalanges, the phalanges were short and expanded resembling bullets, the inferior radioulnar joint was 'v' shaped (arrow marked in Fig.3) with epiphyseal irregularity. Spine revealed dorsal kyphoscoliosis. Fluoroscopy of heart showed densely calcified mitral valve and mildly calcified aortic valve. E.C.G. of RP was normal except for short P-R interval (80 msec). Skiagrams of skull, pelvis, spine, chest were normal. Radiological findings of wrist joints and hands were similar to that RP (Fig. 3). Fluoroscopy of heart showed no calcification in cardiac structures. Findings of two-dimensional and doppler echocardiography of both patients are shown in Table



**Fig. 1. Photograph of RP 16/F and RK 14/F**

#### SCHEIE SYNDROME WITH MULTIVALVULAR INVOLVEMENT

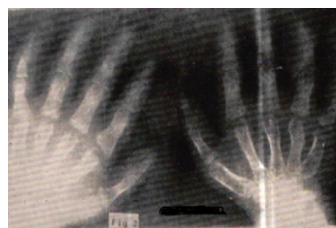

Fig. 2. X—ray of both wrists and hands of RP 16/F

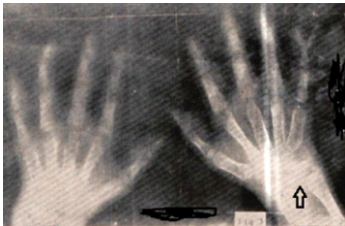


Fig. 3. X—ray of both wrists and hands of RK 14/F

Table-1. 2D echocardiogram and pulsed doppler findings

Case/age/sex	RP 16 F	RK 14 F
Mitral vale	Thickened, calcified and domed. Diastolic spectral broadening and increased flow velocity in the left ventricle distal to leaflets. Calculated gradient 16 mm Hg. Abnormal systolic flow in left atrium proximal to leaflets.	Thickened and domed. Diastolic spectral broadening and increased flow velocity in left ventricle distal to leaflets. Calculated gradient 12 mm Hg. Abnormal systolic flow in left atrium proximal to leaflets.
Aortic valve	Calcified and domed. Increased peak systolic flow velocity in ascending aorta distal to the cusps. No AR. Tricuspid valve Normal movements. Abnormal systolic flow in right atrium proximal to leaflets	Thickened and domed. Increased peak systolic flow velocity in ascending aorta distal to the cusps. No AR Normal movements. Abnormal systolic flow in right atrium proximal to leaflets.
Pulmonary valve	Normal	Normal
Final impression	Severe mitral stenosis, severe aortic stenosis, mild mitral regurgitation, mild tricuspid regurgitation.	Moderate mitral stenosis, moderate aortic stenosis, mild mitral regurgitation, mild tricuspid regurgitation.

Biochemical studies

Urine analysis. 24 hours urine samples of both patients were analysed quantitatively and qualitatively for the different types of glycosaminoglycons and the total uronic acid was estimated following the method of Bitter and Muir.4,5 The results are shown in TableII.

Enzyme studies in leukocytes. α-L-iduronidase was assayed in the leukocytes of both patients and their parents following the method of Rome et al6 using 4-methylumbelliferyl α-L-iduronide as the substrate. The results are shown in Table III.

Discussion

Analysing the clinical, radiological and biochemical findings (urinary excretion of Heparan and Dermatan sulfates, absent leukocytic α-L-iduronidase activity) the above family of two cases comes under type I mucopolysaccharidoses, the Hurler syndrome (MPS 1-H), the Scheie syndrome (MPS 1-S) and the Hurler-Schete compound (MPS 1-HIS). The first one is wholly excluded on the grounds that death ensues usually before the age of ten years, the associated abnormalities being severe and the urinary

excretion ratio of Dermatan and Heparan sulfate being less than 3 : 1. The Hurler-Scheie compound is also ruled out because there is no mental retardation in our cases. Therefore our cases are categorised

into Scheie syndrome. A common feature of all mucopolysaccharidoses is cardiac involvement. In Scheie syndrome the typical cardiac lesion is aortic incompetence and survival beyond the fourth decade is common. McKusick1 described in five cases of Scheie syndrome two basal systolic murmurs,

TableII. Results of urinalysis

Case	Total AMPS in mg/24 hours	%, Fractions		
		He S	Ch A and c	DeS
RP 16/F	29.4	22.13	37.60	42.67
RK 14/F	12	19.5	42.8	37.7
Normal	2.5	11	83	6

\*Expressed as milligrams of uronic acid per 24 hours. HeS—Heparan sulfate; Ch A & C—Chondroitin A and C sulfates; DeS— Dermatan sulfate.

Table III. Results of a-L-iduronidase assay in leukocytes

Case	Age/Sex	Leukocyte a-L-iduro nidase pm/hr/mg protein
RP	16 F	N.D.
RK	14 F	N.D.
Father	48 M	1004
Mother	37 F	1136
Normal		1100 f 200
N.D.—Not detectable		

two apical systolic murmurs and two diastolic murmurs. Wilson.et.al reported cases of MPS I-S with severe aortic stenosis in two brothers. In the cases under discussion we found evidence of aortic stenosis, mitral stenosis, mitral incompetence and tricuspid incompetence based on our clinical, radiological, two-dimensional and doppler echocardiographic findings. Although Wilson et al reported two cases of severe valvular aortic stenosis in Scheie syndrome but definite evidence of mitral valve involvement as described in our cases has not been reported in this or any other report in Scheie syndrome to the best of our knowledge. Schieken et al evaluated noninvasively using M-mode echo- cardiogram, nine cases of mucopolysaccharidoses to find out the involvement of various cardiac structures and reported mitral valve calcification in MPS I-HIS, mitral and aortic valve involvement in MPS VI-A (Maroteaux-Lamy syndrome, classic form) but their only patient with scheie syndrome (MPS I-S) did not reveal any cardiac lesion.

In our cases detailed noninvasive assessment by various methods including two-dimensional and doppler echocardiography were performed and exact diagnosis and severity of various lesions were established. Thus detailed noninvasive assessment by two-dimensional and doppler echocardiographic examination in patients with various mucopolysaccharidoses would enable to detect many more cases with multivalvular involvement and help in decision making for corrective surgery in some of the suitable cases.

Acknowledgement

We are thankful to deparment of biochemistry in evaluation and confirming the diagnosis with reagent 4- methylumbelliferyl iduronidase., also to parents for giving consent for blood analysis,taking X-rays and photographs.

References

1. McKusick VA. The mucopolysaccharido- ses, in heritable disorders of connective tissue. 4th ed., St.Louis: C.V. Mosby, 1972: p 521  
2. Murray RO, Jacobson HG eds. Radiology of the skeletal disorders. 2nd ed., Edinburgh & New York: Churchill L3.Shanks SC, Peter Kerlay eds. A Text Book of X-ray diagnosis. 4th ed. London: H.K. Lewis & Co. Ltd. 1971 : p 589  
4. Bitter T, Muir HM. A modified uronic acid carbazole reaction. Anal Biochem 1962; 4 330-334  
5. DiFerrante N, Rich C. The determination of acid mucopolysaccharides. J Lab Clin Med

1956;48:491-494

6. Rome LH, Weissmann B, Neufeld EF. Direct demonstration of binding of lysosomal enzyme  $\alpha$ -L-iduridase to receptors on cultured fibroblasts. Proc Natl Acad Sci USA 1979;2331-23347.

76 Rudolph AM, Hoffman JLE eds. Paediatrics 17th ed. Connecticut : Appleton-Century-Crofts, Norwalk, 1982 : p 337