

## Anaesthesiology

### KEYWORDS:

Low Thoracic Isobaric Spinal Anaesthesia, Laparoscopic Cholecystectomy, Healthy Individuals.

## TO COMPARE ISOBARIC THORACIC SPINAL ANAESTHESIA VERSUS GENERAL ANAESTHESIA IN LAPAROSCOPY CHOLECYSTECTOMY



Volume - 8, Issue - 2, February- 2023

ISSN (O): 2618-0774 | ISSN (P): 2618-0766

**Nivedika Kumbhare**

PG third year Resident, Department of Anaesthesiology, LNMC & RC, Bhopal, Madhya Pradesh, India.

**Anuj Dubey**

Associate Professor, Department of Anaesthesiology, LNMC & RC, Bhopal, Madhya Pradesh, India.

**C.S. Mishra**

Associate Professor, Department of Anaesthesiology, LNMC & RC, Bhopal, Madhya Pradesh, India.

**Vinay Yadav**

PG third year Resident, Department of Anaesthesiology, LNMC & RC, Bhopal, Madhya Pradesh, India.

**Nupur Chakravarty**

Professor and Head of Department of Anaesthesiology, LNMC & RC, Bhopal, Madhya Pradesh, India.

INTERNATIONAL JOURNAL  
OF PURE MEDICAL RESEARCH



### ABSTRACT

**BACKGROUND-** The laparoscopic cholecystectomy procedure is typically carried out under general anaesthesia, but regional techniques, such as low thoracic isobaric spinal anaesthesia, have been used to manage patients with significant medical problem like coexisting systemic disease, who are deemed to be high risk in general anaesthesia. Segmental spinal anaesthesia has great outcomes in terms of post-operative discomfort, the need for analgesics, relatively fewer complications, and shorter hospital stays. Thus the aim of this study to avoid and minimize the risk of general anaesthesia who does not have any significant comorbidity. So it might be a substitute for a standard laparoscopic cholecystectomy.

**MATERIAL AND METHODS-** Total 60 adult patient with ASA I & II, 18-60 years, with normal coagulation profile, is divided into 2 groups. Group IS (Isobaric)— given 2.5 ml of isobaric preservative free bupivacaine 0.5% (levobupivacaine) + 0.5 mg of Fentanyl at T9-T10/T10-T11 into sub arachnoid space. Group GA – given general anaesthesia using propofol, fentanyl citrate and atracurium besylate. After intubation, ventilation was controlled and balanced anaesthesia was continued with isoflurane. After completion, neuromuscular block was antagonized neostigmine methylsulfate and glycopyrrolate at the end of surgery.

**RESULTS-** Isobaric spinal anaesthesia showed good control in intraoperative as well as postoperative pain control as compared to general anaesthesia. In few patients, there were minor degrees of nausea, vomiting, abdominal pain, shoulder pain, patient anxiety or itching which were treated with standard medication like fentanyl and midazolam. All patients can resume oral intake on the day of surgery.

**CONCLUSIONS-** In conclusion, this study provide evidence that segmental spinal anaesthesia can be used in place of general anaesthesia in healthy individuals also.

### INTRODUCTION-

The gold standard treatment for symptomatic cholelithiasis is laparoscopic cholecystectomy.<sup>1</sup> Although laparoscopic cholecystectomy has obvious advantages over open surgery, postoperative discomfort is still a problem. The effects of pain can lengthen hospital stays and increase morbidity. The inflating of the peritoneal cavity, the use of CO<sub>2</sub>, and the necessary postural

adjustments for the surgery are mostly to blame for its negative effects. Since carbon dioxide is known to irritate the peritoneum, using it during a laparoscopic cholecystectomy frequently results in pain that lasts into the recovery period. Shoulder and upper abdomen pain following laparoscopic surgery cannot be treated with non-steroidal anti-inflammatory medicines alone.<sup>2</sup> General anaesthesia is frequently employed for this procedure.<sup>1</sup> The best anaesthetic approach should result in rapid and complete recovery of awareness, motility, and autonomic functioning in addition to good intra and postoperative analgesia.<sup>3</sup> For laparoscopic surgical procedures, regional anaesthesia, such as low thoracic isobaric spinal anaesthesia, has been described and utilised successfully in morbid patients who were not suitable for general anaesthesia. Numerous studies that showed the effectiveness of thoracic anaesthesia as a regular anaesthetic approach in ASA I and II patients came after that. With a very low effective dose of local anaesthetic medication, low thoracic isobaric spinal anaesthesia at the T9-T10/T10-T11 level blocks the necessary dermatomes necessary for the proposed surgical treatment. The pure S-enantiomer of racemic bupivacaine is known as levobupivacaine, 0.5% isobaric levobupivacaine has a lower toxicity profile than racemic levobupivacaine. In comparison to bupivacaine, it has been demonstrated to have less harmful effects on the circulatory and nervous systems. In general, this helps maintain the strength and muscle tone of the legs. The strength of the sensory blockage increases with the addition of fentanyl. A gradual onset, hemodynamic stability even at high levels of block, a shorter motor block duration leading to early ambulation, and early bladder control are additional benefits. When opposed to lumbar levels, the onset time for isobaric medicines at the thoracic level is not as long. This research was done to compare segmental anaesthesia with general anaesthesia in laparoscopic cholecystectomy.<sup>3</sup>

### MATERIAL AND METHODS-

After we obtained institutional approval and informed consent from patient, total 60 adult patient with Inclusion criteria of ASA I & II, 18-60 years with normal coagulation profile were divided into two equal groups. Exclusion criteria were ASA III or more, any cardiovascular, respiratory, CNS and abdominal disorder. This was the Open Clinical Trial study conducted in the department of Anaesthesiology in L.N. medical college & J.K. hospital of duration of 1 year. Written Informed consent was obtained from each patients. All patients will be visited on the day prior to the surgery and explained in detail about the anesthetic procedure. A detailed pre anesthetic evaluation will be done. Appropriate laboratory and radiological investigation will be requested and evaluated. All

patients will be kept nil per oral from 6 hours prior to the day of surgery and will receive tablet pantop 40 mg as prophylaxis. In the operation theatre standard monitors will be connected (NIBP, ETCO<sub>2</sub>, ECG and Pulse Oximeter), 2 wide bore canula were inserted. Vital parameters will be noted. Appropriate equipments for procedure and drugs related to complication will be kept ready before procedure. Total 60 adult patients which were divided into 2 groups. Group IS (Isobaric)— given 2.5 ml of isobaric preservative free levobupivacaine 0.5% (5mg/ml) + 0.5 ml (25mcg) of Fentanyl at T9-T10/T10-T11 into sub arachnoid space. Group GA – given general anaesthesia using propofol (1.5-2mg/kg), fentanyl citrate (1.5-2mcg/kg) and atracurium besylate. Balanced anaesthesia was continued with isoflurane 1% to 1.2%. After intubation, ventilation was controlled with Tidal Volume of 6-8 ml/kg and PaCO<sub>2</sub> 35 to 45 mmHg. Neuromuscular block was antagonized with 2.5mg of neostigmine methylsulfate and 0.5mg glycopyrrolate at the end of surgery. In GA group, intraoperatively, antihypertension and analgesic were used as per the patients response towards pneumoperitoneum. We commonly used alfa blockers (dexmedetomidine) for trachy cardia and hypertension while IV paracetamol/tramadol used for analgesia. After complication of procedure, both the group patients were shifted to SICU for further monitoring of vitals and analgesics requirements.

**SURGICAL TECHNIQUE -**

Laparoscopic cholecystectomy was performed by a surgeon experienced in laparoscopic surgery, with the following modifications of the surgical technique. 1. Surgical duration of time should be less than 60 minutes. 2. The intraabdominal pressure was set at a maximum of 11-12mmHg instead of the usual 14-15mmHg. 3. Minimum number of trocars should be used. 4. Gentle surgical manipulation was employed, especially near the diaphragm and the pylorus to minimize shoulder pain and vomiting, respectively.

**PARAMETERS TO BE EVALUATED-**

1. Intraoperative and postoperative hemodynamic parameters  
 2. Analgesia duration  
 3. Side effects  
 4. Recovery and patient satisfaction at follow up.

**STATISTICAL ANALYSIS-**

A standard form of data will be made. Data was compiled in Excel Sheet by using MS Excel 2019, it was analysed for relevant outcome and p value less than 0.05%. was considered significant. Anova test was applied in different variable to see the level of significance.

**RESULTS-**

**DEMOGRAPHIC COMPARISON**

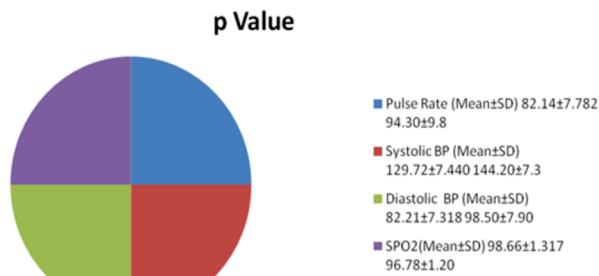
PARAMETERS	ISOBARIC (N=30)	GENERAL ANAESTHESIA (N=30)
AGE	18-60 YEARS	18-60 YEARS
GENDER	20 FEMALE +10 MALES	15FEMALES + 15 MALES
WEIGHT	50-60KGS	50-60KGS
HEIGHT	150-170CMS	150-170CMS

There was no demographic statistical significant difference (p value <0.005) between two groups in terms of age, gender, height , weight.

**HEMODYNAMIC COMPARISON**

PARAMETERS	GROUP IS (N=30)	GROUP GA (N=30)	P VALUE
PULSE RATE (MEAN±SD)	82.14±7.882	94.30±9.8	<0.0001
SYSTOLIC BP (MEAN±SD)	129.72±7.440	144.20±7.3	<0.0001
DIASTOLIC BP (MEAN±SD)	82.21±7.318	98.50±7.90	<0.0001
SPO2 (MEAN±SD)	98.66±1.317	96.78±1.20	<0.0001

There was an good control in intraoperative hemodynamic parameters in isobaric group as compared to general anaesthesia group.



**TOTAL ANALGESIC REQUIREMENT**

TIME (IN MINUTES)	ISOBARIC	GENERAL ANAESTHESIA
0 MINUTES	—	1
10 MINUTES	2	4
20 MINUTES	1	1
30 MINUTES	—	2
40 MINUTES	—	1
50 MINUTES	—	1
60 MINUTES	—	—

Isobaric spinal anaesthesia showed good control in intraoperative as well as postoperative pain control as compared to general anaesthesia. In few patients, there were minor degrees of nausea, vomiting, abdominal pain, shoulder pain, patient anxiety or itching which were treated with standard medication like fentanyl for pain and midazolam for anxiety. All patients can resume oral intake on the day of surgery.

**DISCUSSION**

One of the most popular elective general procedures, a laparoscopic cholecystectomy is carried out under general anaesthesia and is regarded as a minimally invasive procedure. If the outcomes were compared to those of general anaesthesia, it was discovered that spinal anaesthesia, by inducing neuraxial blockade, is associated with less postoperative mortality as well as fewer complications, such as deep vein thrombosis, pulmonary embolism, pneumonia, respiratory depression, myocardial infarction, and renal failure<sup>1</sup>. Laparoscopic cholecystectomy pain is not a significant issue, but minimally invasive surgery has gained popularity because of the quick and easy recovery. When compared to general anaesthesia, laparoscopic cholecystectomy under spinal anaesthesia used for postoperative pain management with fewer complications.

In our study, we included 60 patients with ASA I and II, and we found that patient satisfaction was excellent and side effects were limited in this group. Only 3 patients in the isobaric group report shoulder pain, and 1 patient reports itching. 22 patients in the GA group report post-operative abdominal pain, and 5 patients report nausea and vomiting post operatively. Only 2 patients in the isobaric group need midazolam, while 3 patients need fentanyl. Compared to the general anaesthetic group, only 2 patients in the isobaric group need analgesics after 10 minutes, and 1 patient after 20 minutes intraoperatively.

When J. Van Zundert used this technique to anaesthetize a patient with severe obstructive lung disease in 2006, a new phase of research on segmental spinal anaesthesia puncturing SAS at T10 for laparoscopic cholecystectomy was initiated. He administered segmental spinal anaesthetic to a patient who had severe respiratory disease. Under segmental spinal anaesthesia, the doctors were able to execute cholecystectomy on this patient effectively<sup>16</sup>

Yousef GT et al. conducted a research to compare spinal anaesthesia (segmental thoracic or conventional lumbar) with the gold standard general anaesthesia. A total of 90 patients undergoing elective laparoscopic cholecystectomy were randomly divided into three equal groups to undergo laparoscopic cholecystectomy with low-

pressure CO<sub>2</sub> pneumoperitoneum under segmental thoracic (TSA group), traditional lumbar (LSA group), or general anaesthesia (GA group). For the GA group, tracheal intubation, sevoflurane, fentanyl, atracurium, and propofol were employed. The three groups were contrasted in terms of intraoperative parameters, postoperative analgesia and recovery, complications, and patient and surgeon satisfaction. The authors came to the conclusion that segmental Thoracic Spinal Anaesthesia results in improved hemodynamic stability, less need for vasopressors, and earlier ambulation and discharge with a higher level of patient comfort. Compared to traditional lumbar spinal anaesthetic, it provides higher patient satisfaction, making it ideal for day surgery. Imbelloni LE et al. showed similar improved hemodynamics during surgery in individuals receiving segmental spinal anaesthetic<sup>13,14</sup>

Hamad MA, El-Khattary OA et al. performed laparoscopic cholecystectomy under spinal anaesthesia in small series of healthy patient by using nitrous oxide in spite of Carbon dioxide as the insufflating gas as we used in our study and concluded that it can be performed successfully under spinal anaesthesia and is well tolerated<sup>1</sup> which is equivalent to our study Longo MA, Cavalheiro BT, de Oliveira Filho GR. et al found that spinal anaesthesia is better as compared to general anaesthesia in order to control the intraoperative pain only 3.4% cases required conversion into general anaesthesia which is also similar to our study<sup>8</sup>. Kour L, Katoch ML et al. use levobupivacaine in thoracic spinal anaesthesia in laparoscopic cholecystectomy and found that longer duration of sensory block with hemodynamic stability<sup>15</sup> It is also parallel to our study. Yousef GT, Lasheen AE et al perform laparoscopic cholecystectomy under thoracic spinal anaesthesia and found better postoperative pain control, better hemodynamic stability with higher degree of patient satisfaction<sup>1</sup> which is also similar to our study.

In light of this, spinal anaesthesia is a promising anaesthetic technique for laparoscopic procedures that, with the right improvements, may one day become the standard anaesthetic technique for elective laparoscopic cholecystectomy in healthy patients.

#### SCOPE OF FUTURE EXPERIMENTAL/FURTHER STUDIES

One of the most often performed elective general surgical procedures is the laparoscopic cholecystectomy. The availability of effective postoperative pain management is crucial because it is a prime candidate to be conducted as a day case or short stay procedure. Future experimental investigations may involve administering intraperitoneal local anaesthetic to lessen postoperative pain prior to surgical closure. Due to its prolonged duration of action, ropivacaine or Bupivacaine itself (levobupivacaine) is a great option for intraperitoneal local anaesthesia.

#### CONCLUSION

In conclusion, this study provide evidence that segmental spinal anaesthesia can be used in place of general anaesthesia also in healthy individuals in terms of postoperative pain relief. Secondly, segmental spinal anaesthesia was better in terms of hospital stay, cost, side effects related to general anaesthesia and patient-related satisfaction.

#### REFERENCES-

1. Hamad MA, El-Khattary OA. Laparoscopic cholecystectomy under spinal anesthesia with nitrous oxide pneumo-peritoneum: A feasibility study. *Surg Endosc.* 2003;17:1426-8.
2. Segmental spinal anesthesia for cholecystectomy in patient with severe lung disease, *Br J Anaesth*, 2006 vol. 96 (page 464-6).
3. Naresh Wamanrao Paliwal, Jayesh Ingle, Sunil Lawhale, Amol Dhakulkar. Segmental spinal vs general anaesthesia in patients undergoing laparoscopic cholecystectomy: A comparative study. *MedPulse International Journal of Anesthesiology.* June 2020; 14(3): 77-83.
4. Hansen G, Diablos PA, Steinert R (1977) Pulmonary complications, ventilation and blood gases after upper abdominal surgery *Acta Anaesthesiol Scand* 21:211-215
5. Alkhamisi NA, Peck DH, Lomax D, Darzi AW. Intraperitoneal aerosolization of bupivacaine reduces postoperative pain in laparoscopic surgery: A randomized

6. prospective controlled double-blinded clinical trial. *Surg Endosc.* 2007;21:602-6
6. Gramatica L Jr Brasco O, Mercado Luna A et al. Laparoscopic cholecystectomy performed under regional anaesthesia in patients with obstructive pulmonary disease. *Surg Endosc* 2002; 16(3):472-475.
7. Luchetti M, Palomba R, Sica G, Massa G, Tufano R. Effectiveness and safety of combined epidural and general anesthesia for laparoscopic cholecystectomy. *Reg Anesth.* 1996 Sep-Oct;21(5):465-9. PMID: 8896010.
8. Longo MA, Cavalheiro BT, de Oliveira Filho GR. Laparoscopic cholecystectomy under neuraxial anesthesia compared with general anesthesia: Systematic review and meta-analysis. *J Clin Anesth.* 2017 Sep;41:48-54. doi: 10.1016/j.jclinane.2017.06.005. Epub 2017 Jun 26. PMID: 28802605.
9. Sinha R, Gurwara AK, Gupta SC. Laparoscopic surgery using spinal anesthesia. *JSL.* 2008;12(2):133-138.
10. PARADIS B. Segmental spinal anesthesia. *Treat Serv Bull.* 1948 Jul-Aug;3(7):41-5
11. Van Zundert AAJ, Stultiens G, Jakimowicz JJ et al. Segmental spinal anesthesia for cholecystectomy in a patient with severe lung disease. *Br J Anaesth*, 2006;96:464-466.
12. Belzarena SD. Comparative Study between thoracic epidural block and general anesthesia for oncologic mastectomy. *Rev Bras Anesthesiol.* 2008;58:561-8.
13. Yousef GT, Lasheen AE. General anesthesia versus segmental thoracic or conventional lumbar spinal anesthesia for patients undergoing laparoscopic cholecystectomy [retracted in: *Anesth Essays Res.* 2013 Sep-Dec;7(3):293]. *Anesth Essays Res.* 2012;6(2):167-173
14. Imbelloni LE. Spinal anesthesia for laparoscopic cholecystectomy: Thoracic vs. Lumbar Technique. *Saudi J Anaesth.* 2014 Oct;8(4):477-83.
15. Kour L, Katoch ML. Comparison of levobupivacaine vs bupivacaine in thoracic spinal anesthesia for laparoscopic cholecystectomies. *Int J Res Med Sci* 2019;7:4568-72.
16. Van Zundert AA, Stultiens G, Jakimowicz JJ, Peek D, Van der Ham WG, Korsten HH, Wildsmith JA. Laparoscopic cholecystectomy under segmental thoracic spinal anaesthesia: a feasibility study. *Br J Anaesth.* 2007;98(5):682-6.
17. Boddy AP, Mehta S, Rhodes M. The effect of intraperitoneal local anesthesia in laparoscopic cholecystectomy: a systematic review and meta-analysis. *Anesth Analg.* 2006 Sep;103(3):682-8. doi: 10.1213/01.ane.0000226268.06279.5a. PMID: 16931681.
18. Ellakany M. Comparative study between general and thoracic spinal anesthesia for laparoscopic cholecystectomy. *Egypt J Anaesth.* 2013;29:375-81.