

## Surgery

**KEYWORDS:** Laparoscopy;  
Portal Vein Thrombosis; Gastric  
Bypass

## PORTAL VEIN THROMBOSIS AFTER ROBOTIC GASTRIC BYPASS: CASE REPORT AND REVIEW OF THE LITERATURE



Volume-4, Issue-8, August - 2019

ISSN (O): 2618-0774 | ISSN (P): 2618-0766

**Manuel Aceves  
Avalos\***

MD, Obesidad y Laparoscopia Avanzada (OLA), Centro Médico Puerta de Hierro Sur, Guadalajara, Jalisco, México \*Corresponding Author acevesma1@gmail.com

**Eric Iván Barragán  
Veloz**

MD, Obesidad y Laparoscopia Avanzada (OLA), Centro Médico Puerta de Hierro Sur, Guadalajara, Jalisco, México

**Jesús Raúl Pérez  
Gómez**

MD, Obesidad y Laparoscopia Avanzada (OLA), Centro Médico Puerta de Hierro Sur, Guadalajara, Jalisco, México

**Arturo Martínez  
Medrano**

MD, Obesidad y Laparoscopia Avanzada (OLA), Centro Médico Puerta de Hierro Sur, Guadalajara, Jalisco, México

**Oscar Ramón  
Guzmán Chávez**

MD, Hospital civil Fray Antonio Alcalde, Guadalajara, Jalisco México

**Eduardo Aceves  
Velázquez**

MD, Internal Medicine, Centro Médico Puerta de Hierro Sur

**Jose Israel Acosta  
Uriostegui**

MD, Radiology Department, Centro Médico Puerta de Hierro Sur

### Article History

Received: 28.03.2019

Accepted: 19.06.2019

Published: 10.08.2019



### ABSTRACT:

Portal vein thrombosis (PVT) is a rare but potentially lethal complication after laparoscopic procedures. Patients with obesity undergoing bariatric surgery are at increased risk of having venous thromboembolism because they have a hypercoagulable and inflammatory state. Clinical manifestations are frequently non-specific; the broad spectrum ranges in asymptomatic patients to life-threatening bowel infarction. We present the case of a female 30 years old with a body mass index (BMI) of 43 kg/m<sup>2</sup> refractory to conventional weight-loss treatment. Robotic Roux-en-Y Gastric Bypass has been made without any problem and the postoperative evolution of the patient was uneventful. Postoperative IV contrast CT scan discovered a partial portal vein occlusion. We started Clexane 40mg SC daily since the first postoperative day. After the hematologic protocol the patient was diagnosed with an Antiphospholipid syndrome as the origin of the PVT. Diagnosis and treatment to prevent intestinal ischemia and a potential necrosis should not wait; a high index of suspicion is required. Anticoagulant therapy is generally satisfactory preventing thrombus extension, achieving partial recanalization and avoiding new thrombotic events.

### INTRODUCTION

Obesity is currently a major health problem worldwide, in developed countries affects up to 25% [1, 2]. A growing number of patients are undergoing surgical treatment for their morbid obesity, appears to be the most cost-effective method. [3] Laparoscopic Roux-en-Y gastric bypass (LRYGP) is one of the most performed bariatric procedures in the world with great effectiveness and safety. [4]. However bariatric procedures are not free from complications, the incidence is reported to be as high as 7%. [5]

Portal vein thrombosis (PVT) is a rare but potentially lethal complication after laparoscopic procedures [6]. Present in 5% to 15% of all mesenteric ischemic events. [7,8] Its presentation, treatment and outcomes remain poorly understood.[9] Possible etiologic factors can be derived from changes because of increased intra-abdominal pressure due to pneumoperitoneum, intraoperative manipulation, portal hypertension, oral contraceptive use, bowel obstruction, damage of splenic endothelium and systemic thrombophilic diseases like thrombophilia, protein C deficiency or antiphospholipid syndrome [10,11]. Patients with obesity undergoing bariatric surgery are at increased risk of having venous thromboembolism because they have a hypercoagulable and inflammatory state [12]

PVT has great variability in its clinical presentation from a clinical finding in an asymptomatic patient to life-threatening bowel infarction.[13] Clinical manifestations are frequently non-specific, allowing subclinical acute PVT to progress to chronicity with associated portal hypertensive complications. [14] It has been described since 1994 PVT after laparoscopic procedures without involving lesions to the portal venous system [15] Several cases have recently been published following laparoscopic procedures. [16] This article reviews the literature about PVT after laparoscopic surgery. During literature search few publications are described as an uncommon complication, with risk factors, causes, clinical presentation, diagnosis options and current treatment. [17]

### CASE REPORT

We present the case of a female 30 years old with a body mass index (BMI) of 43 kg/m<sup>2</sup> despite optimizing medical treatment, there was no satisfactory weight reduction and entered a bariatric surgery program. In the preoperative evaluation the patient had no hypertension, diabetes mellitus or previous abdominal surgeries. Any hematologic or thrombotic disease. In preoperative imaging studies we discovered a left hepatic lobe lesion of approximately 2x2 centimeters at the preoperative ultrasound so we made a complementary CT scan with IV contrast finding only a small benign hemangioma.

The patient was scheduled to a Robotic Roux-en-Y Gastric Bypass plus excisional biopsy of the hepatic lesion. Surgery without any problem only attracts attention to a great diameter of gastric fundus veins and a slight splenomegaly. Pathology reported: Benign cavernomatous hemangioma from biopsy of hepatic lesion. Postoperative IV contrast CT scan discovered a partial portal vein occlusion. The postoperative evolution of the patient was uneventful being discharged at postoperative day 3. We started Clexane 40mg SC daily since the first postoperative day and an appointment with Hematology service.

Continued follow-up with good evolution and adequate weight loss. Eighteen months ahead the patient present ferropenic anemia, studies are carried out discovering in Panendoscopy esophageal varicose veins Grade III with no bleeding where ligation is decided (Figure 1,2). We asked for a new CT scan appreciating an evident portal vein thrombosis and portal hypertension (Figure 3). After the hematologic protocol the patient was diagnosed with an Antiphospholipid syndrome as the origin of the PVT. She has been treated with Enoxaparin anticoagulation for 6 months. In the third month of treatment presented a severe variceal bleeding requiring esophageal varicose ligation.

The patient was scheduled to laparoscopic gastric fundus and distal esophageal devascularization successfully. The size of varicose veins has decreased in a two post operative months control Panendoscopy. She still continues with Enoxaparin anticoagulation (6 months until now). Control CT scan with evidence of PVT partial recanalization (Figure 4, 5). The patient has had a satisfactory evolution, asymptomatic, no anemia or bleeding data. Adequate weight loss of gastric bypass to date.

## DISCUSSION

Portal vein thrombosis it is partial or total obstruction of the blood flow secondary to the formation of a thrombus. This thrombus may form at any level of the portal vein until it extends into the splenic or mesenteric vein.[18,19] The risk of intestinal ischemia can be high if the thrombus expands several veins or the occlusion is total.[16,20] PVT after a laparoscopic procedure is rare, but a pathology of great clinical importance, due it's a potential life-threatening condition.[21,22] Over the past decade an increase of laparoscopic weight loss surgery as seen, therefore multiple studies have been reported of PVT in bariatric population. [23, 24, 25] A systematic literature review documents 18 cases of PVT after laparoscopic surgery, of which seven are secondary to gastric bypass. [16]

There is a prothrombotic state and venous stasis that increases the risk of PVT such as obesity, medication, thrombophilia, increased intra-abdominal pressure, or damage to splenic endothelium. [27] There are special cases like genetic coagulopathies that have association to PVT, include factor V Leiden, protein C and S deficiency and hyperhomocysteinemia. [28] Antiphospholipid syndrome or antiphospholipid antibody syndrome (APS or APLS), is an autoimmune, hypercoagulable state caused by antiphospholipid antibodies. [29] Our patient had no personal history of prothrombotic hematologic condition or family history suggesting genetic coagulopathy previous to surgery. Several studies are carried out after the thrombotic event of the patient, finding antiphospholipid antibodies. In our bariatric group all patients receive routinely preoperative prophylaxis unless contraindicated, subcutaneous heparin injection and perioperative pneumatic compression stockings.

The symptomatology after laparoscopic surgery of portal vein thrombosis is usually very variable, difficult to diagnose clinically, reason for which most of the cases delayed its management. [30] The range of symptoms varies widely from fully asymptomatic patient to severe patient due to bowel infarction. [31]

Ball et al. report in a retrospective analysis of 112 patients who underwent total proctocolectomy and found a 10% incidence of symptomatic PVT. [32]

S alman AlSabah et al. report in a recent publication of case series, median onset of diagnosis from 28 days, and incidence of PVT after laparoscopic sleeve gastrectomy (LSG) from .39% within the reported in the literature. [33]

The definitive diagnosis of PVT is made with noninvasive imaging. [34] The elective image modality for evaluation of portal vein thrombosis is CT with intravenous contrast injection, in all patients with non-specific abdominal pain following laparoscopic surgery and with important risk factors for venous thrombosis. [35] This modality detects filling defects in the Porto-mesenteric venous system, as well as the extension of PVT. Is a great tool that identifies secondary complications to PVT as intestinal ischemia or necrosis. [36] We advocate our patient follow-up with CT scan to confirms the presence or dissolution of thrombus and prevent recurrence. Until today it continues with partial presence of thrombus.

There is another diagnostic method of great utility in PVT, the transabdominal color Doppler ultrasonography (US). Is a non-invasive method of great value in its identification, although is more operator-dependent than CT scan. Is use most often in PVT follow-up. [37]

PVT treatment focuses on preventing its extension, achieving recanalization and avoiding new thrombotic events. Some treatments have been described, include thrombolysis, thrombectomy and anticoagulation. [38] The most used treatment modality is anticoagulation with portal vein recanalization up to 50% after 6 months of treatment. [39]

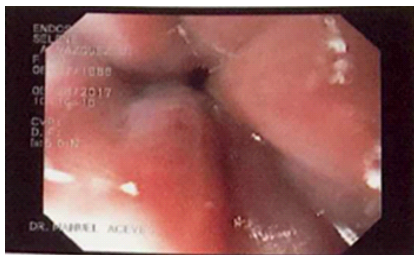Cenedese et al. in his retrospective study of nine cases with extensive mesenteric venous thrombosis suggested initial conservative management of PVT; posteriorly implement surgical intervention if the patient worsens clinical condition with signs of intestinal necrosis or perforation. [40] Serum lactate is considered a seric marker of great utility in the diagnosis of progressive intestinal ischemia. [41]

Condat et al. Demonstrates in 31 cases of portal or mesenteric thrombosis 27 with complete or partial recanalization with anticoagulant therapy. [42] Evidence in the literature suggests that subsequent to PVT, treatment with anticoagulation should be extended up to 6 months if no prothrombotic state is found. [43]

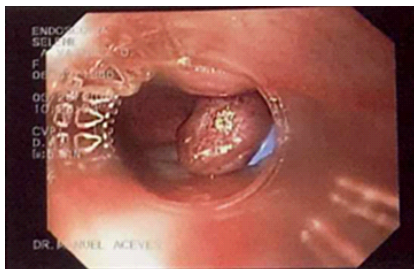
Our patient is part of the group of patients at high risk for venous thromboembolism, and its management is carried out as suggested by the practice guidelines. [44] In a recent paper including laparoscopic bariatric surgery of 5706 patients, 17 patients (0.3%) had PVT, 16 after sleeve gastrectomy and 1 patient posterior to adjustable gastric banding. [45] This shows that PTV is a rare complication in bariatric surgery, it is important to have knowledge and high suspicion to prompt diagnosis and avoid a potentially fatal condition

## CONCLUSION

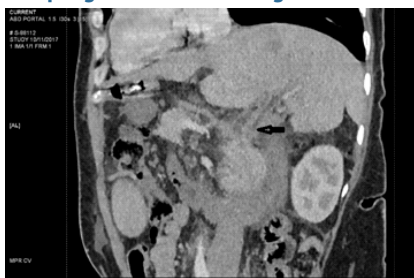In this paper we described a patient who present with PVT after Robotic Roux-en-Y Gastric Bypass with antiphospholipid syndrome. PVT is a rare and potentially serious complication secondary to laparoscopic bariatric surgery and symptomatology is variable and vague, if there is. Diagnosis and treatment to prevent intestinal ischemia and a potential necrosis should not wait and high index of suspicion is required. The evidence suggests anticoagulant therapy is generally satisfactory preventing thrombus extension, achieving recanalization and avoiding new thrombotic events. Careful follow-up is important to evaluate PVT on long-term patient's outcomes. Larger studies are needed in the literature to help establish prophylactic protocols, prompt recognition, and optimal treatment.



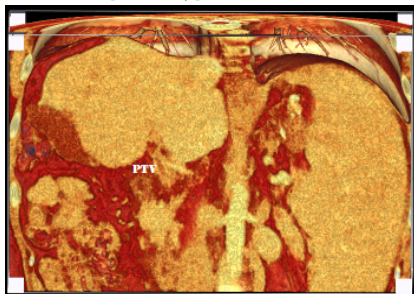
**Figure 1. - Esophageal varicose veins Grade III with no bleeding**



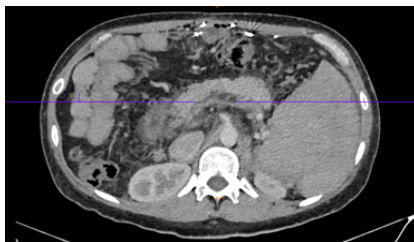
**Figure 2. - Esophageal varicose veins ligation is decided**



**Figure 3. - CT scan sagittal image appreciating an evident portal vein thrombosis and portal hypertension.**



**Figure 4. - Control CT scan with evidence of PVT partial recanalization.**



**Figure 5. - Control CT scan with evidence of PVT partial recanalization**

## REFERENCES

- Ogden CL, Carroll MD, Curtin LR, et al. Prevalence of overweight and obesity in the United States. *JAMA* 2006;295:1549-55
- Li Z, Bowerman S, Heber D. Health ramifications of the obesity epidemic. *Surg Clin North Am.* 2005;85(4):681-701.
- Sjostrom L, Lindroos AK, Peltonen M, et al. Lifestyle, diabetes and cardiovascular risk factors 10 years after bariatric surgery. *N Engl J Med.* 2004;351:2683-93
- Hanipah ZN, Schauer PR. Surgical treatment of obesity and diabetes. *Gastrointest Endosc Clin N Am* 2017 Apr;27(2):191-211
- Birkmeyer NJ, Dimick JB, Share D, et al. Michigan Bariatric Surgery Collaborative: hospital complication rates with bariatric surgery in Michigan. *JAMA* 2010;304(4):435-42
- Villagrán R, Smith G, Rodríguez Walter et al. Portomesenteric Vein Thrombosis After Laparoscopic Sleeve Gastrectomy: Incidence, Analysis and Follow-Up in 1236 Consecutive Cases. *Obes Surg.* 2016;26:2555-2561
- Grendell JH, Ockner RK. Mesenteric venous thrombosis. *Gastroenterology.* 1982; 82(2):358-372
- Pigeure M, Seguy D, Arnalsteen L, et al. Laparoscopic gastric bypass complicated by portal venous thrombosis and severe neurological complications. *Obes Surg.* 2008;18:1203-1207
- Valla D, Condat B. Portal vein thrombosis in adults: pathophysiology, pathogenesis and management. *J Hepatol.* 2000;32(5):865-71
- Allaix ME, Krane MK, Zoccali Marco. Postoperative Portomesenteric Venous Thrombosis: Lessons Learned From 1,069 Consecutive Laparoscopic Colorectal Resections. *World J Surg* 2014;38:976-984
- Samama MM. An epidemiologic study of risk factors for deep vein thrombosis in medical outpatients: the Sirius study. *Arch Intern Med.* 2000;160(22):3415-20.
- Bellager DE, Hargroder AG, Greenway FL. Mesenteric venous thrombosis after laparoscopic sleeve gastrectomy. *Surg Obes Relat Dis.* 2010;6(1):109-11
- Goiten D, Matter I, Raziel A, et al. Portomesenteric thrombosis following laparoscopic bariatric surgery: incidence, patterns of clinical presentation, and etiology in a bariatric patient population. *JAMA Surg.* 2013;148(4):340-6
- Hashikura Y, Kawasaki S, Munakata Y, Hashimoto S, Hayashi K, Makuuchi M. Effects of peritoneal insufflation on hepatic and renal blood flow. *Surg Endosc.* 1994;8:759-763
- Sogaard KK, Astrup LB, Vilstrup H, Gronbaek H. Portal vein thrombosis; risk factors, clinical presentation and treatment *BMC Gastroenterology* 2007; 7:34
- James AW, Rabl C, Westphalen AC et al. Portomesenteric venous thrombosis after laparoscopic surgery: a systematic review. *Arch Surg* 2009; 144:520-526
- Lee CM, Cirangle PT, Jossart GH. Vertical gastrectomy for morbid obesity in 216 patients: report of two-years results. *Surg Endosc.* 2007;21(10):1810-6
- Preventza OA, Habib FA, Young SC, Penney D, et al. Portal vein thrombosis: an unusual complication of laparoscopic cholecystectomy. *J Soc Lap Surg.* 2005;9:87-90
- Baikauli J, Delaney CP, Senagore AJ, et al. Portal vein thrombosis after laparoscopic sigmoid colectomy for diverticulitis: report of a case. *Dis Colon Rectum.* 2003;46:550-553
- Parikh S, Ellman L, Warshaw AL. Portal vein thrombosis. *Am J Med.* 2010;123:111-119
- Kemppainen E, Kokkola A, Siren J, Kiviluoto T. Superior mesenteric and portal vein thrombosis following laparoscopic Nissen fundoplication. *Dig Surg.* 2000;17:279-281
- Jakimowicz J, Stultiens G, Smulders F. Laparoscopic insufflations of the abdomen reduces portal venous flow. *Surg Endosc.* 1998;12:129-132
- Swartz DE, Felix EL. Acute mesenteric venous thrombosis following laparoscopic Roux-en-Y gastric bypass. *J Soc Lap Surg.* 2004;8:165-169
- Denne JL, Kowalski C. Portal vein thrombosis after laparoscopic gastric bypass. *Obes Surg.* 2005;15:886-889
- Jacob M, Rosenberg BS, Maureen T. Portal vein thrombosis following laparoscopic Sleeve Gastrectomy for morbid obesity. *JSL.* 2002;16:639-643
- Sternberg A, Alfici R, Bronek S, et al. Laparoscopic surgery and splanchnic vessel thrombosis. *Journal of Laparoendoscopic and Advanced Surgical Techniques.* 1998;8(2):65-8
- Primignani M, Martinelli I, Bucciarelli P, et al. Risk factors for thrombophilia in extrahepatic portal vein obstruction. *Hepatology.* 2005;41:603-608
- Sidhesh B, Ravi A, Vijay D, et al. Isolated protein S deficiency presenting as catastrophic systemic arterial and subsequently venous thrombosis. *Australasian Medical Journal* 2012;5:424-428
- Gomez JA, Cervera R. Diagnosis and classification of the Antiphospholipid syndrome. *Journal of Autoimmunity.* 2014;48:20-25
- Kassir R, Loimier P, Breton C, et al. Mesenteric venous thrombosis after laparoscopic sleeve gastrectomy: pathophysiology and review of literature. *Journal of Current Surgery.* 2014;4(4):3:1
- Alsina E, Ruiz-Tovar J, Alpera MR, et al. Incidence of Deep veins thrombosis and thrombosis of the portal mesenteric axis after laparoscopic sleeve gastrectomy. *Journal of Laparoendoscopic and Advanced Surgical Techniques.* 2014;601-5
- Ball CG, Mac Lean AR, Buie WD et al. Portal vein thrombosis after ileal pouch-anal anastomosis: its incidence and association with pouchitis. *Surg Today* 2007; 37:552-557
- AlSabah S, AlRuwaished M, Almazzezi S et al. Portomesenteric Vein Thrombosis Post-Laparoscopic Sleeve Gastrectomy: Case Series and Literature Review. *Obes Surg* 2017;09(3):1-10
- Bardbury Ms, Kavanagh PV, Bechtold RE, et al. Mesenteric venous thrombosis: diagnosis and no invasive imaging. *Radiographics.* 2002;22:527-541
- Haddad MC, Clark DC, Sharif HS, et al. MR, CT and ultrasonography of splanchnic venous thrombosis. *Gastrointest Radiol.* 1992;17:34-40
- Bradbury MS, Kavanagh PV, Bechtold RE et al. Mesenteric venous thrombosis: diagnosis and noninvasive imaging. *Radiographics* 2002; 22:527-541
- Pieters PC, Miller WJ, DeMeo JH et al. Evaluation of the portal venous system: complementary roles of invasive and noninvasive imaging strategies. *Radiographic* 1997; 17:879-895
- Hall TC, Garcea G, Metcalfe M et al. Management of acute non-cirrhotic and non-malignant portal vein thrombosis: a systematic review. *Word J Surg.* 2011 35:2510-2520
- Plessier A, Murad S, Hernández-Guerra M et al. A prospective multicentric follow-up study on 105 patients with acute portal vein thrombosis (PVT): results from the European network for vascular disorders of the liver (EN-VIE). *Hepatology* 46(suppl 1):310
- Cenedese A, Monneuse O, Gruner L. Initial management of extensive mesenteric venous thrombosis: retrospective study of nine cases. *World J Surg.* 2009;33:2203-8
- Lange H, Jackel R. Usefulness of plasma lactate concentration in the diagnosis of acute abdominal disease. *Eur J Surg.* 1994;160:381-4
- Condat B, Pessiones F, Hillaire S. Recent portal or mesenteric venous thrombosis: increased recognition and frequent recanalization on anticoagulant therapy. *Hepatology.* 2000;466-70
- Ponziani FR, Zocco MA, Campanale C, et al. Portal vein thrombosis: insight into pathophysiology, diagnosis, and treatment. *World J Gastroenterol* 2010;16:143-155
- Douketis JD, Berger PB, Dunn AS, et al. The perioperative management of antithrombotic therapy: American College of Chest Physicians Evidence Based Clinical Practice Guidelines (8th Edition). *Chest* 2008;133:299S-339S